

OCINIO DI



ASSOCIAZIONE ITALIANA
RIPROTESIZZAZIONE

UNIVERSITÀ
VERONA
Istituto di
ORTODONZIA
ORTODONZIA
ORTODONZIA
ORTODONZIA

SACRO CUORE
DON CALABRIA
IRCCS

IX CONGRESSO NAZIONALE
IL RECUPERO DELLE GEOMETRIE ARTICOLARI
NELLE REVISIONI PROTESICHE
VERONA | GRAN GUARDIA | 7-8 MARZO 2024



CHIESTI



Enrico Gervasi

Casa di Cura Giovanni XXIII, Monastier di Treviso

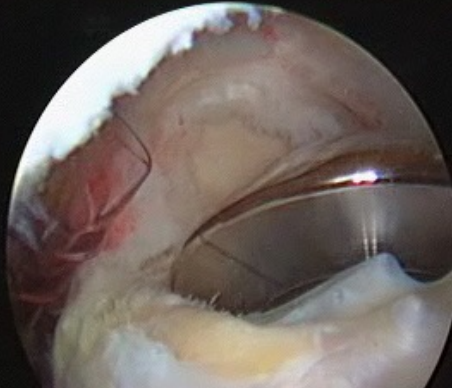
Quando la revisione fallisce?



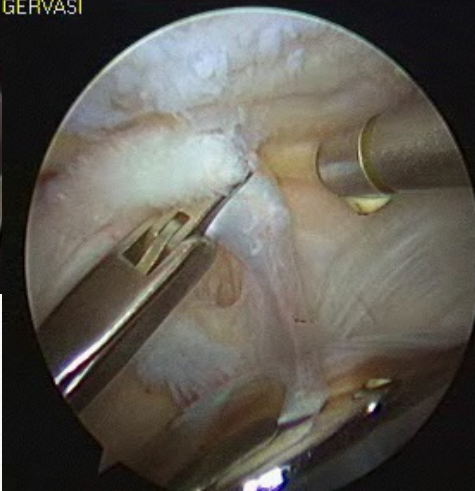HEMIARTHROPLASTY REVISION FAILURES

Massive cuff and hemi: arthroscopic repair

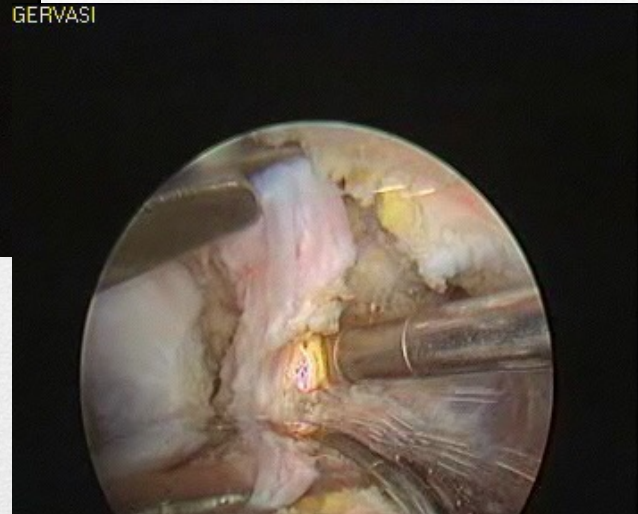
GERVASI



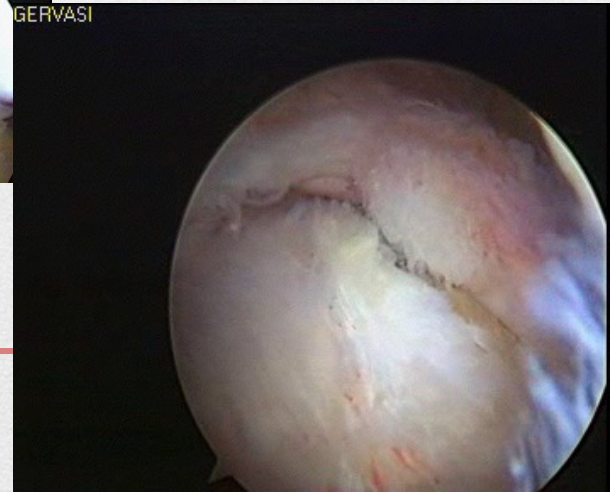
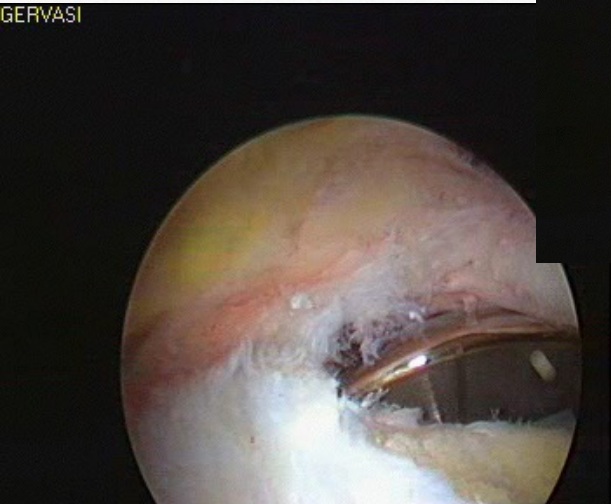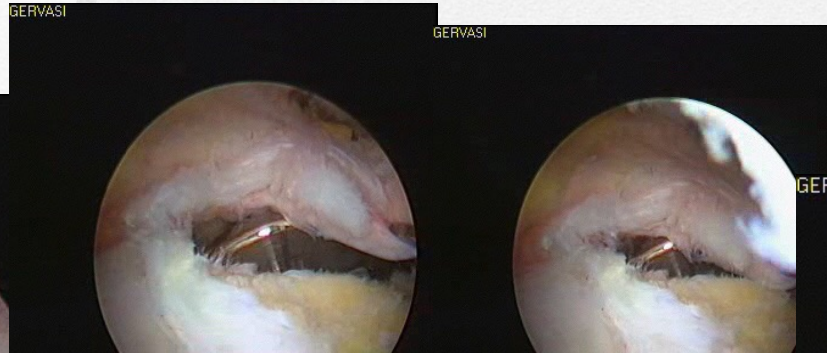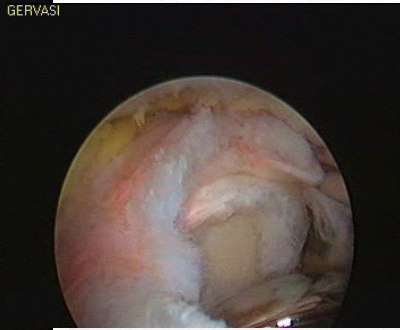
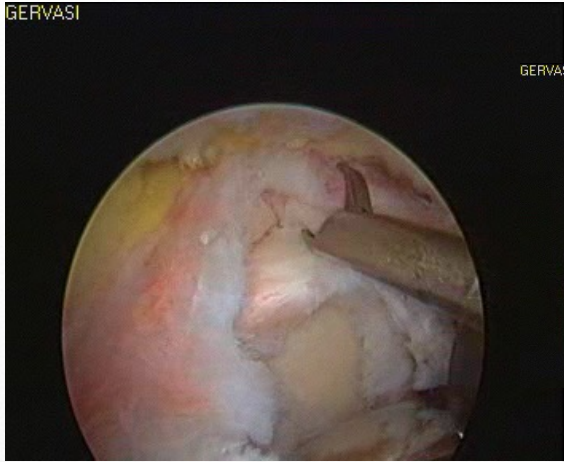GERVASI

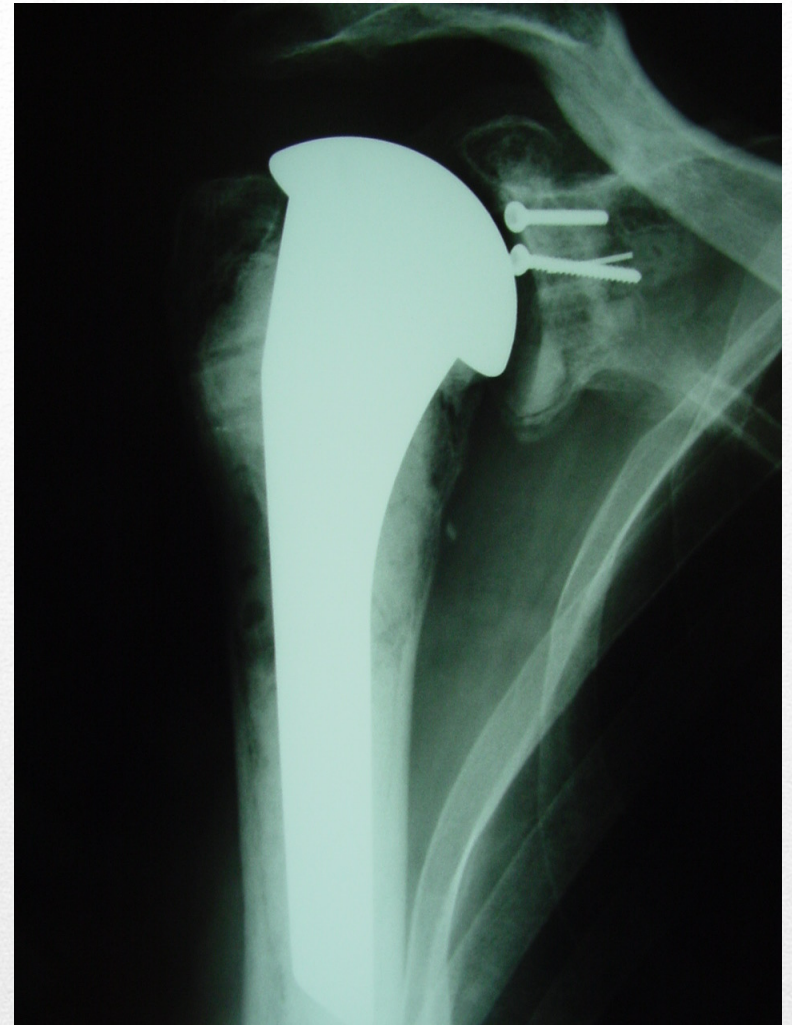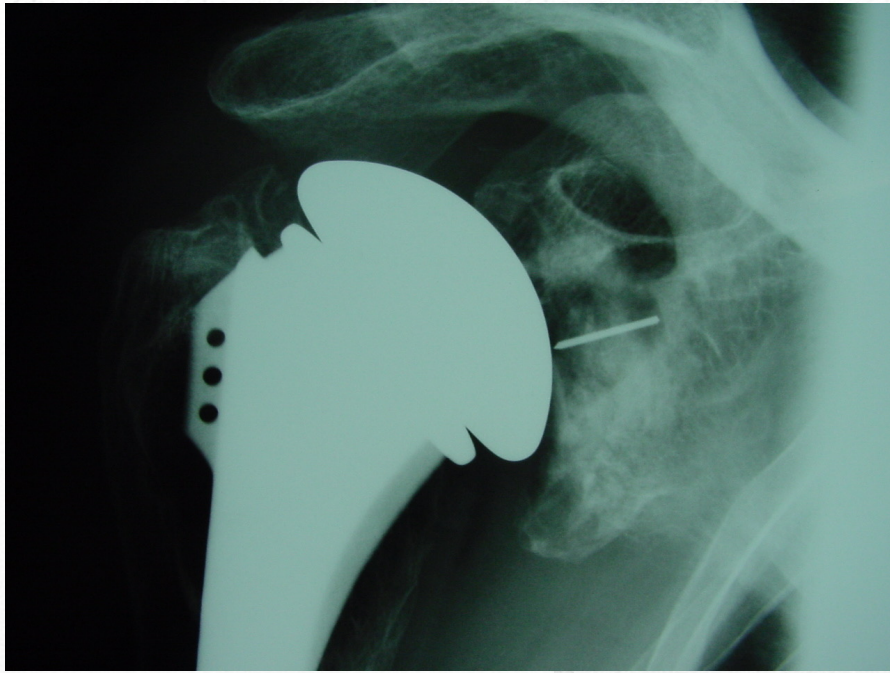


GERVASI



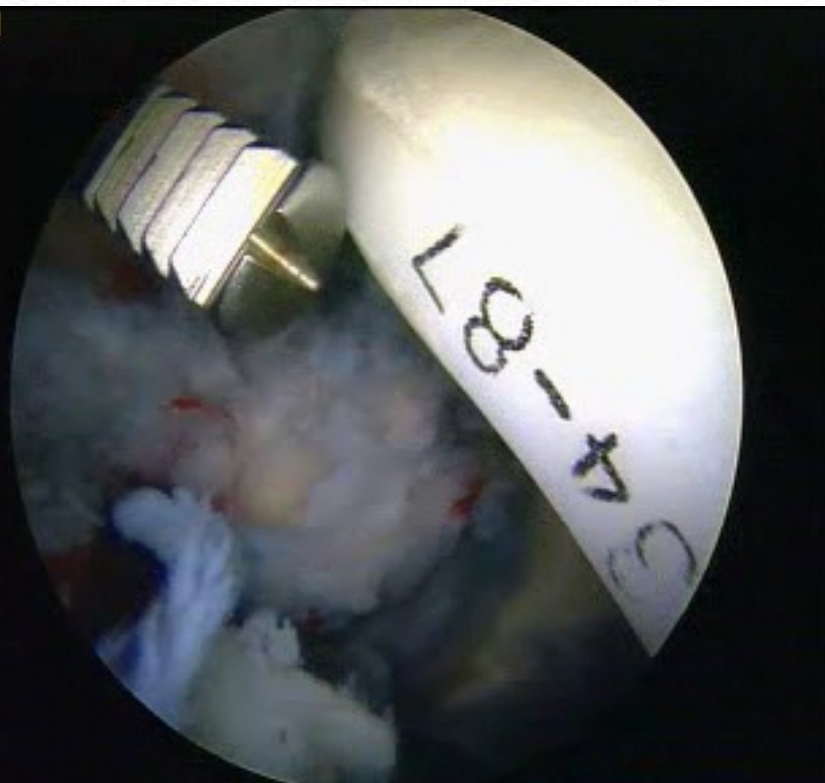
Massive cuff and hemi: arthroscopic repair



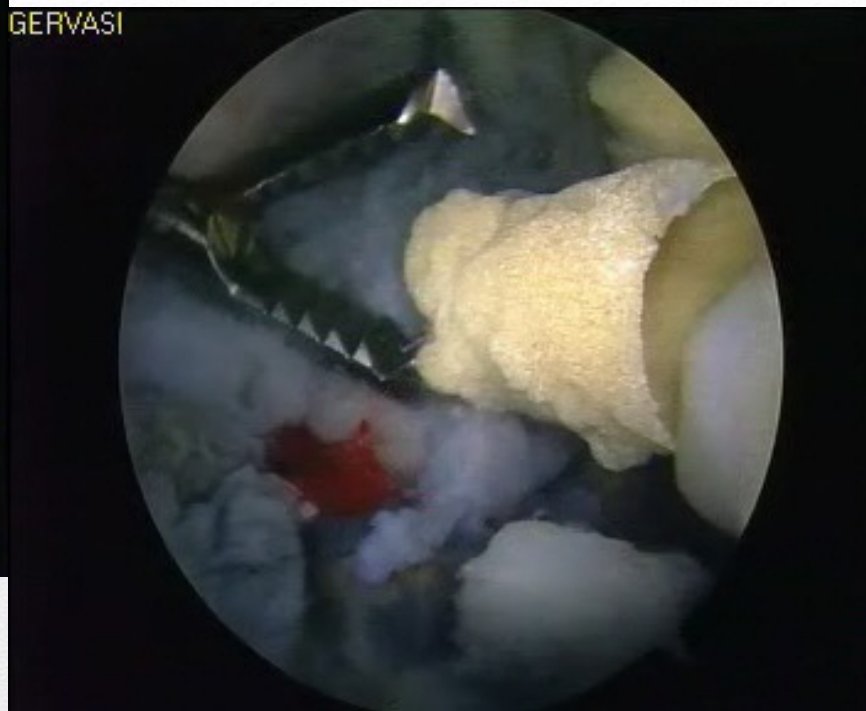

**Arthritis in
youngs**

GERVASI

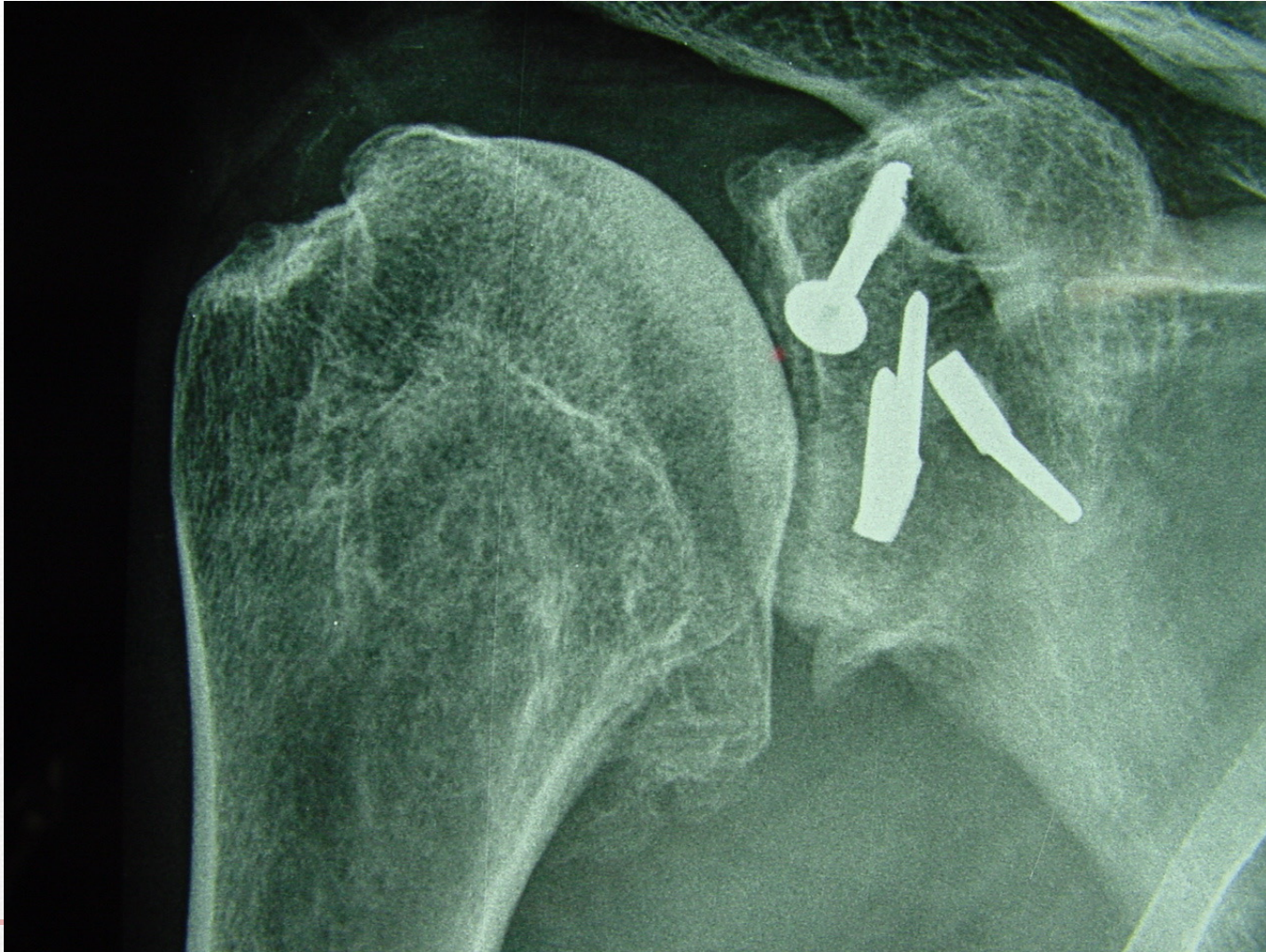


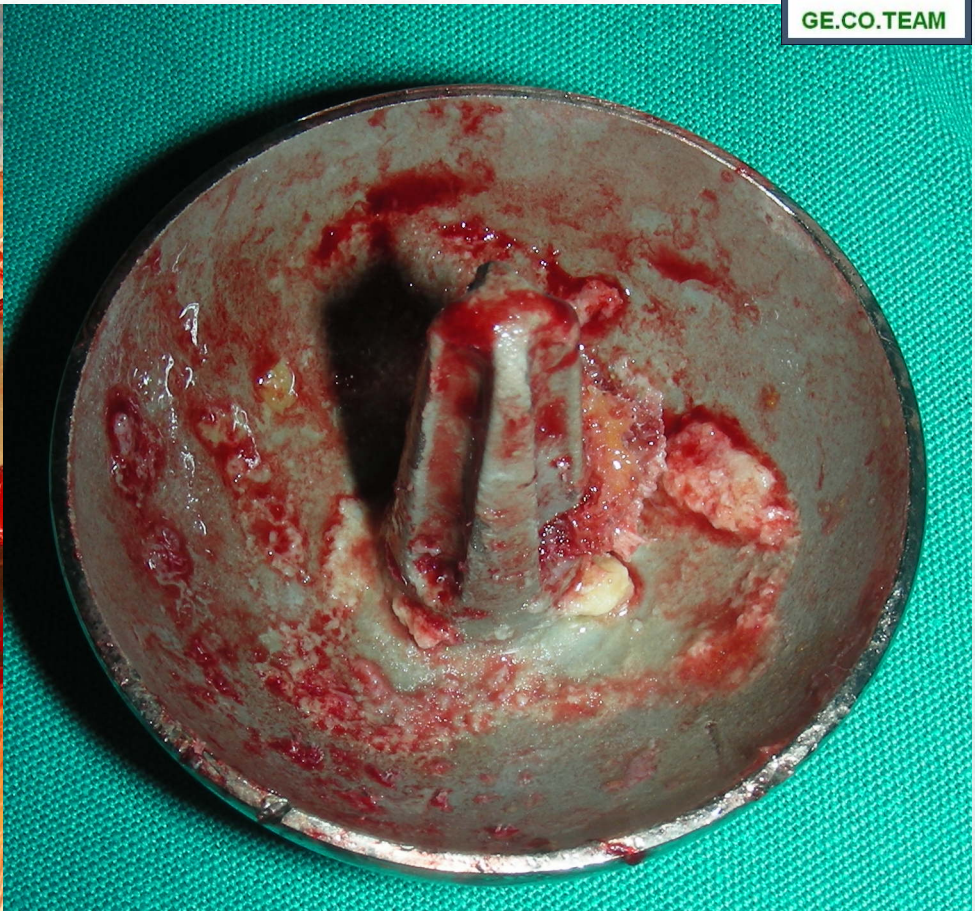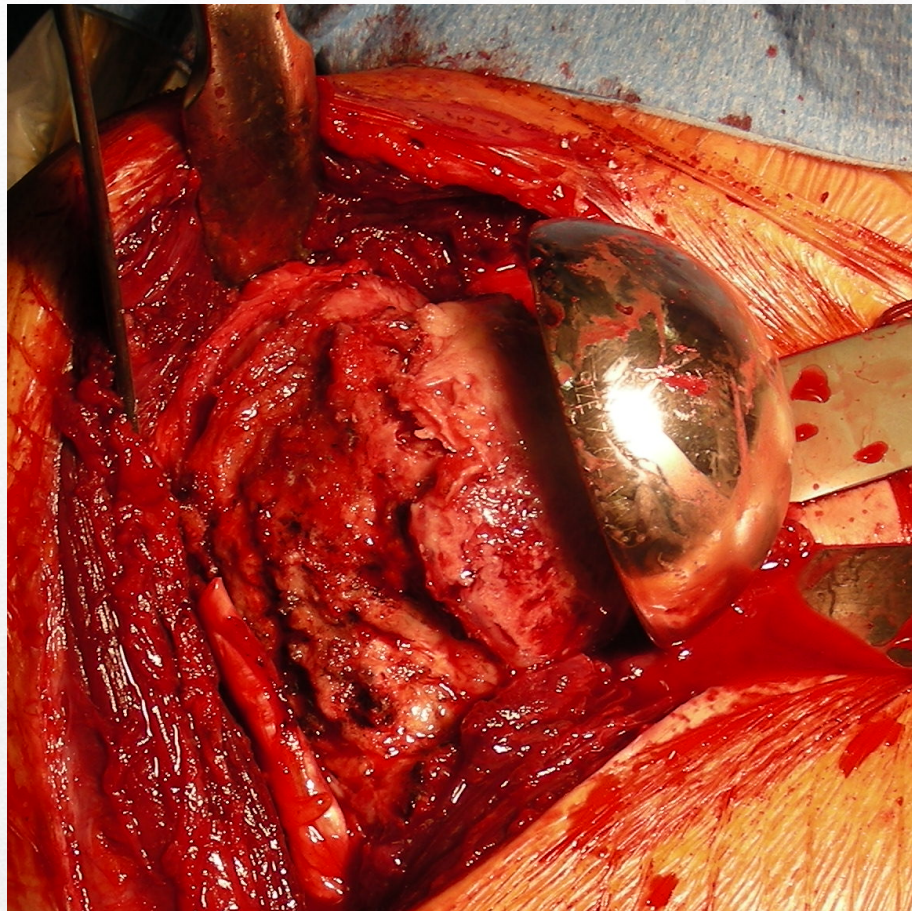
GERVASI

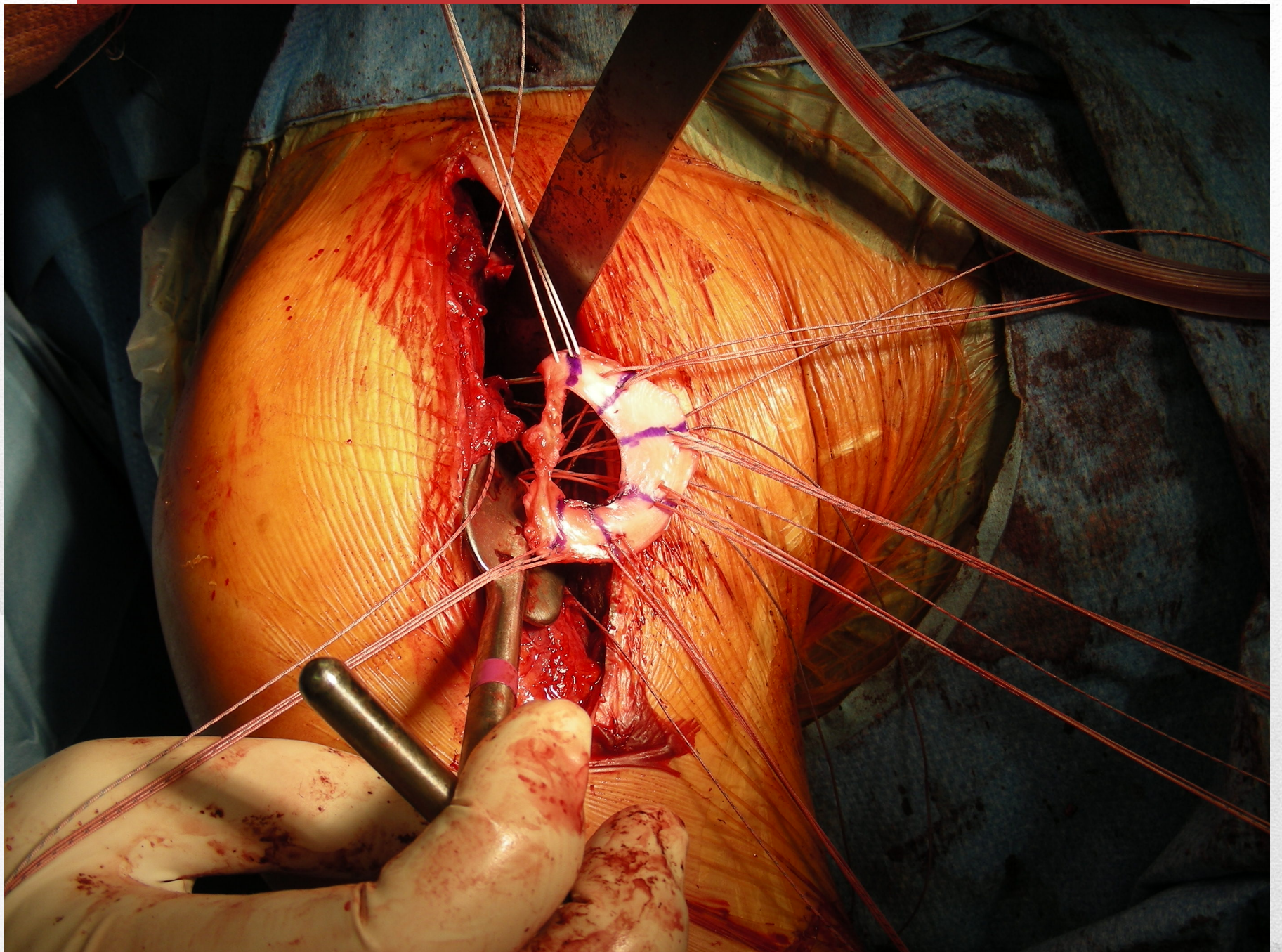


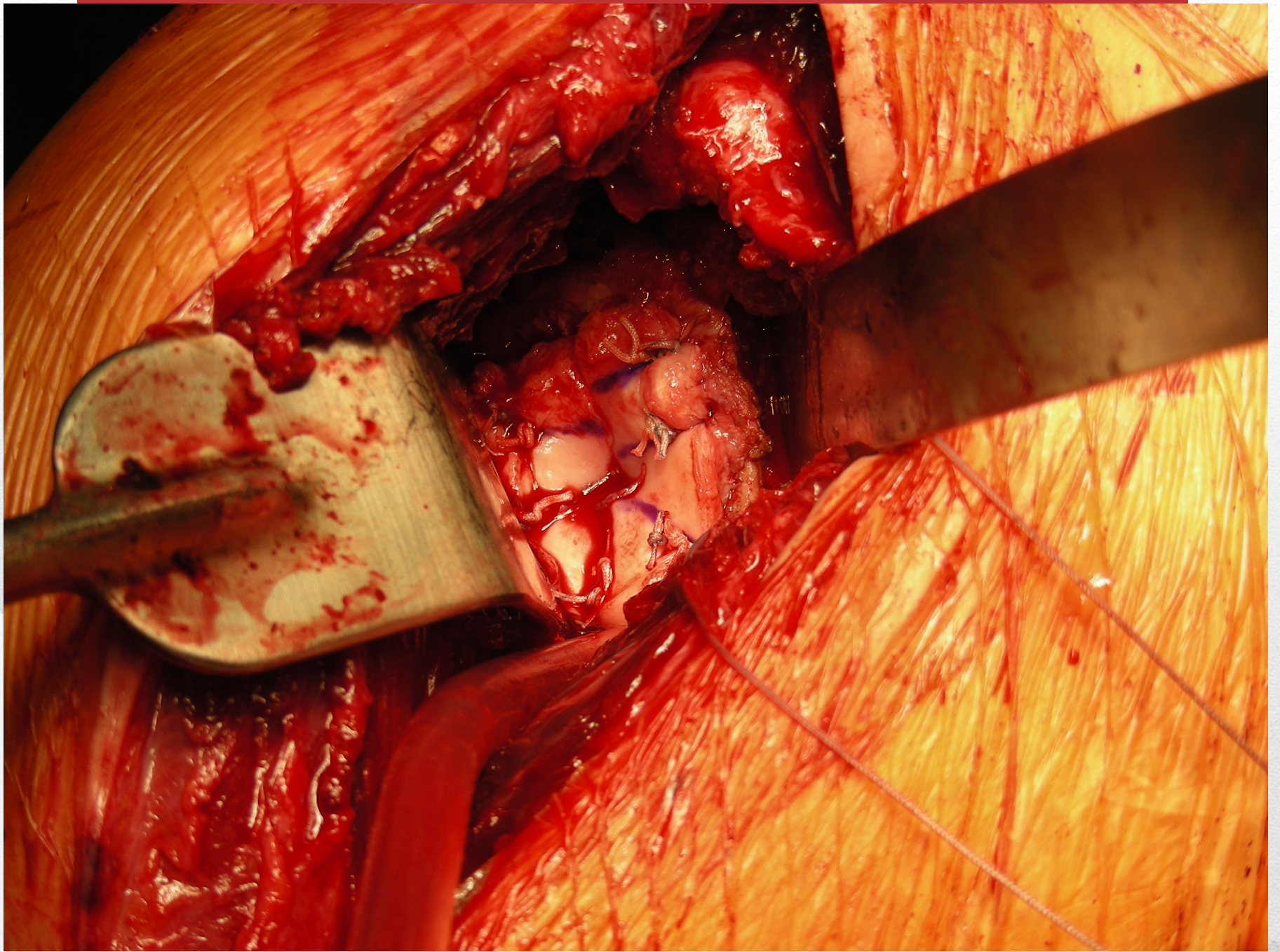
From total to hemi

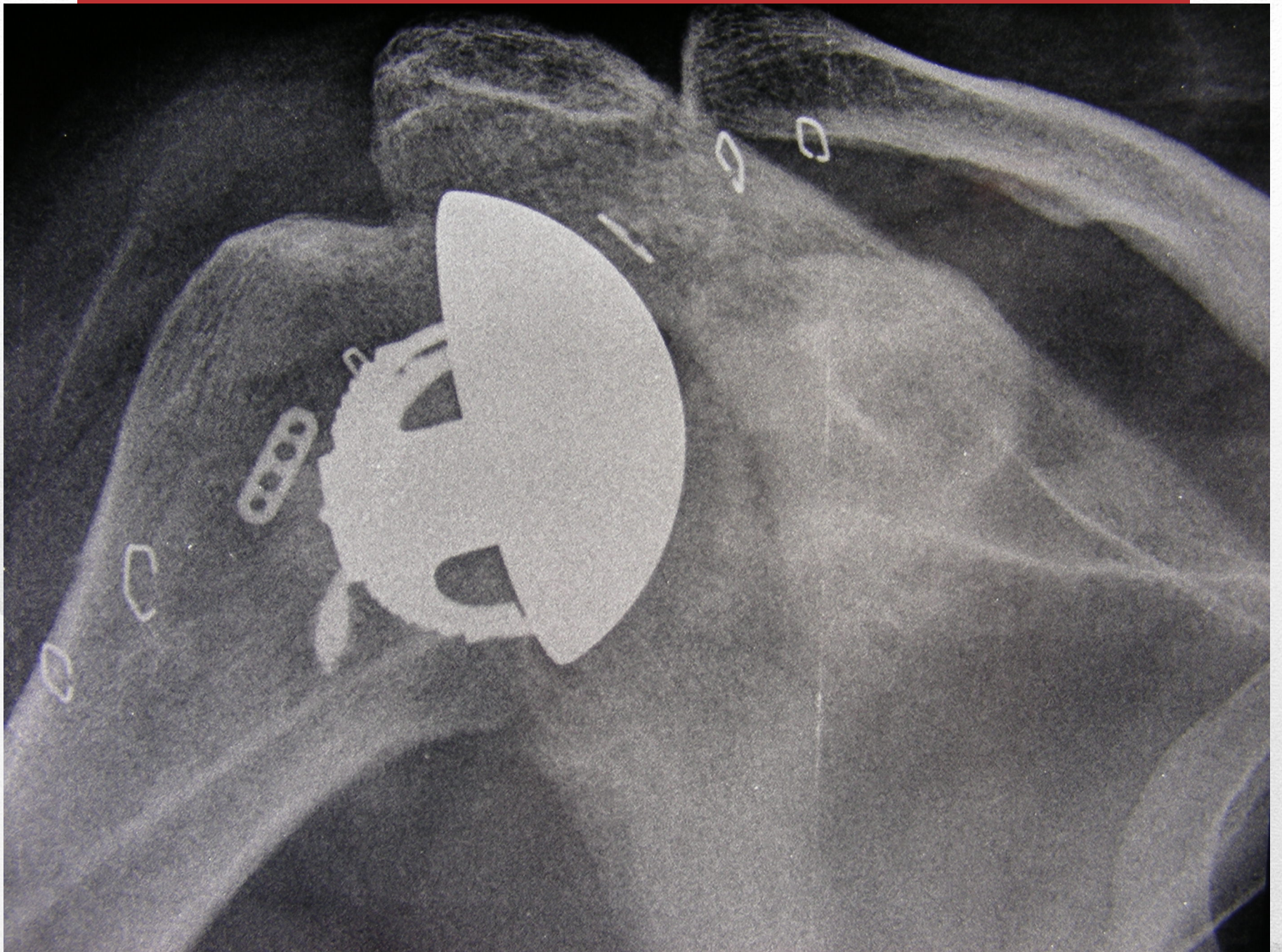
Post capsulorrhaphy arthritis









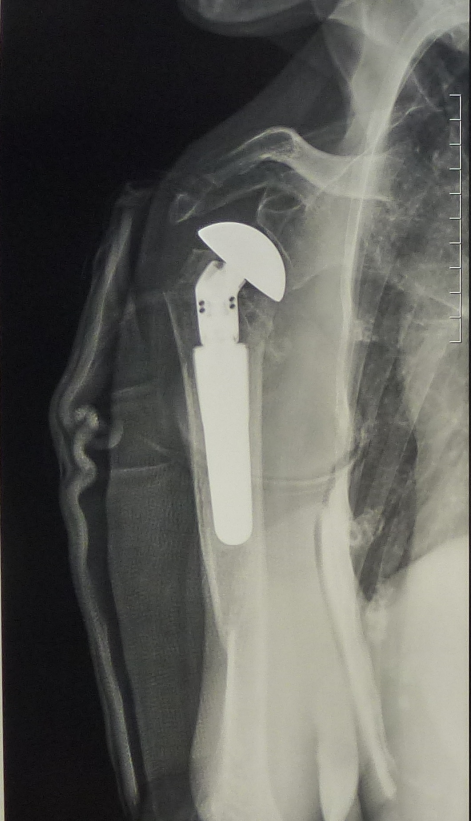
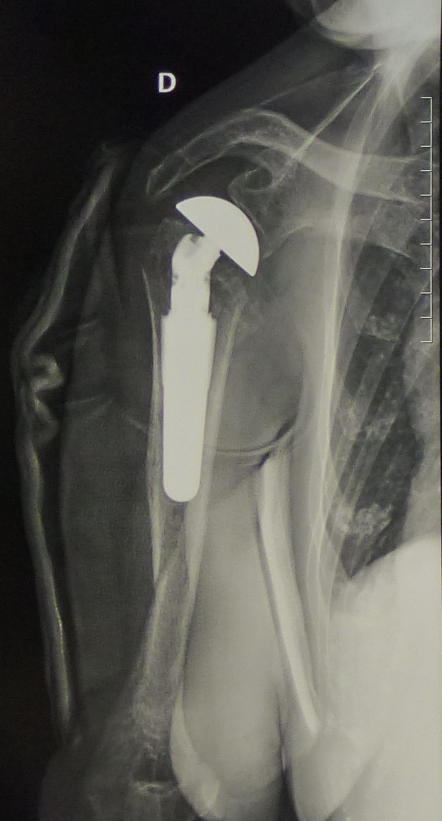


The background features a large, dark red polygon in the upper left quadrant, a lighter red polygon to its right, and a grey polygon in the lower right. A thin red horizontal line is positioned near the bottom of the page.

FRACTURES

CLEMENTE, ROSANNA
05320 DOB: 06 Sep 1937 R331581 Series # Image #4
Osp. LATISANA CLEMENTE, ROSANNA
95320 DOB: 06 Sep 1937 R331581 Series # Image #4
199.4 mA 7.98 mAs 70 kVp 40 ms
0.717 mGy 5.275 dGy/cm2
22-Jun-2012 14:55:27
UExp: 1.97 μGy CDExp: 1.57 μGy
DEI: 0.63 [0.42 - 1.27]

CLEMENTE, ROSANNA
05320 DOB: 06 Sep 1937 R331581 Series # Image #5
Osp. LATISANA
95320 DOB: 06 Sep 1937 R331581 Series # Image #5
199.7 mA 7.99 mAs 70 kVp 40 ms
0.718 mGy 5.282 dGy/cm2
22-Jun-2012 14:55:35
UExp: 1.39 μGy CDExp: 1.11 μGy
DEI: 0.45 [0.42 - 1.27]

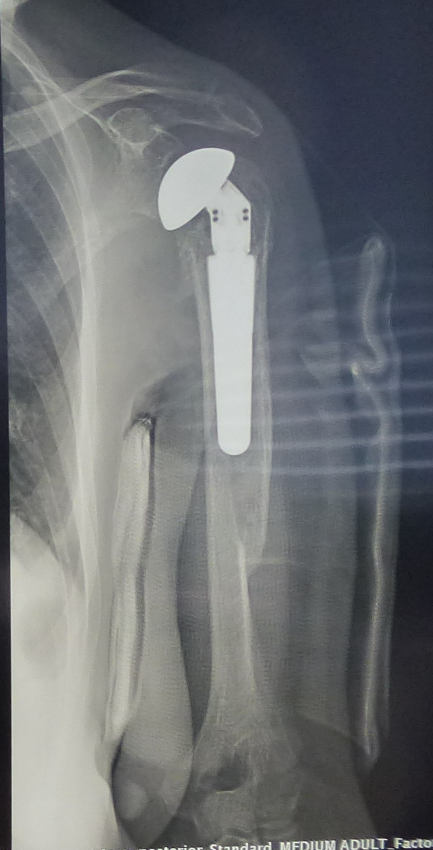
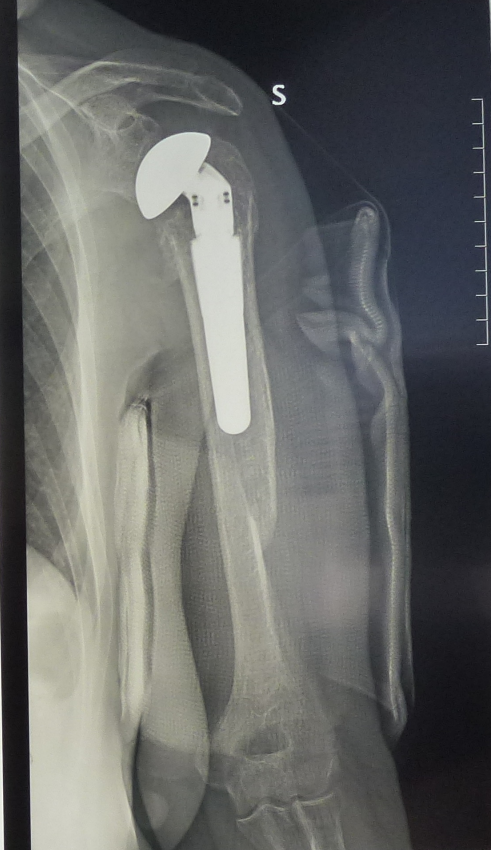
Humerus_antero-posterior_Standard_MEDIUM ADULT_Factory4 Pr
antero-posterior Both
CROPPED Reduce Size
WW: 4361 WC: 6286 Zoom=70%

Humerus_antero-posterior_Standard_MEDIUM ADULT_Factory4 Pr
antero-posterior Both
CROPPED Reduce Size
WW: 4247 WC: 6406 Zoom=70%

CLEMENTE, ROSANNA
05320 DOB: 06 Sep 1937 R331581 Series # Image #7
Osp. LATISANA CLEMENTE, ROSANNA
95320 DOB: 06 Sep 1937 R331581 Series # Image #7
200.1 mA 8.02 mAs 70 kVp 40 ms
0.719 mGy 5.296 dGy/cm2
22-Jun-2012 14:54:19
UExp: 2.97 μGy CDExp: 2.36 μGy
DEI: 0.95 [0.42 - 1.27]

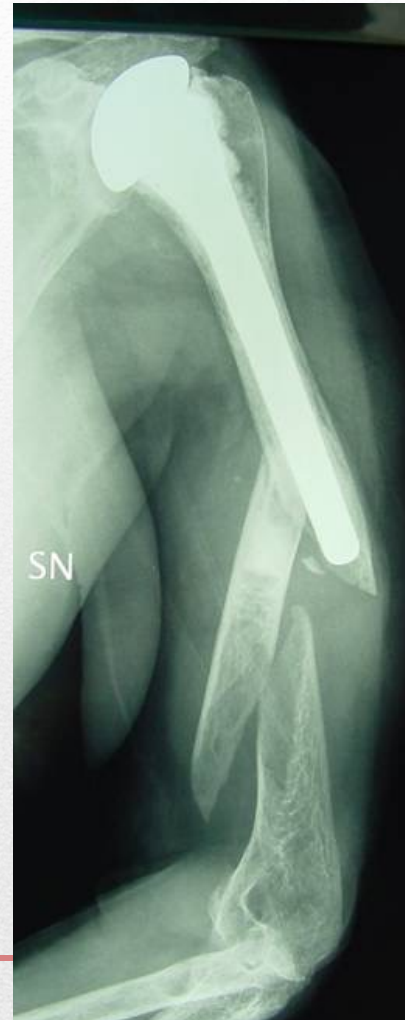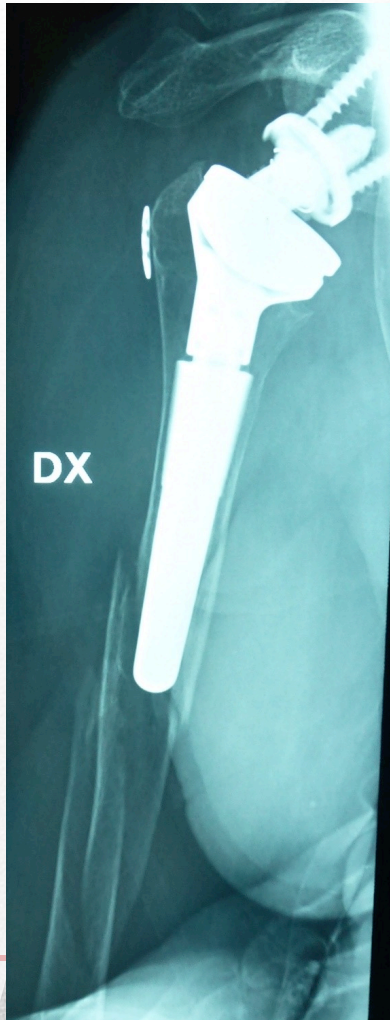CLEMENTE, ROSANNA
05320 DOB: 06 Sep 1937 R331581 Series # Image #8
Osp. LATISANA
95320 DOB: 06 Sep 1937 R331581 Series # Image #8
199.9 mA 8.00 mAs 70 kVp 40 ms
0.718 mGy 5.287 dGy/cm2
22-Jun-2012 14:54:29
UExp: 2.93 μGy CDExp: 2.34 μGy
DEI: 0.94 [0.42 - 1.27]

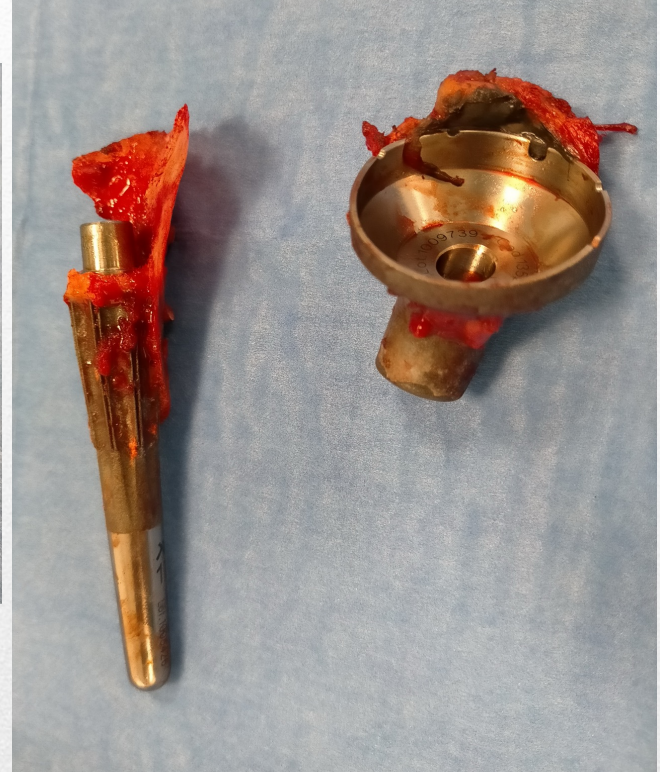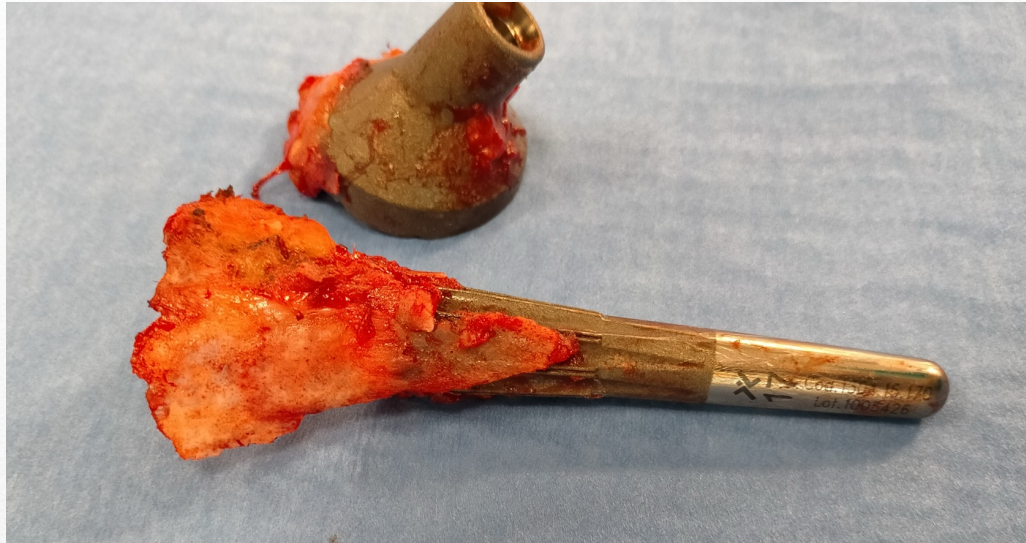


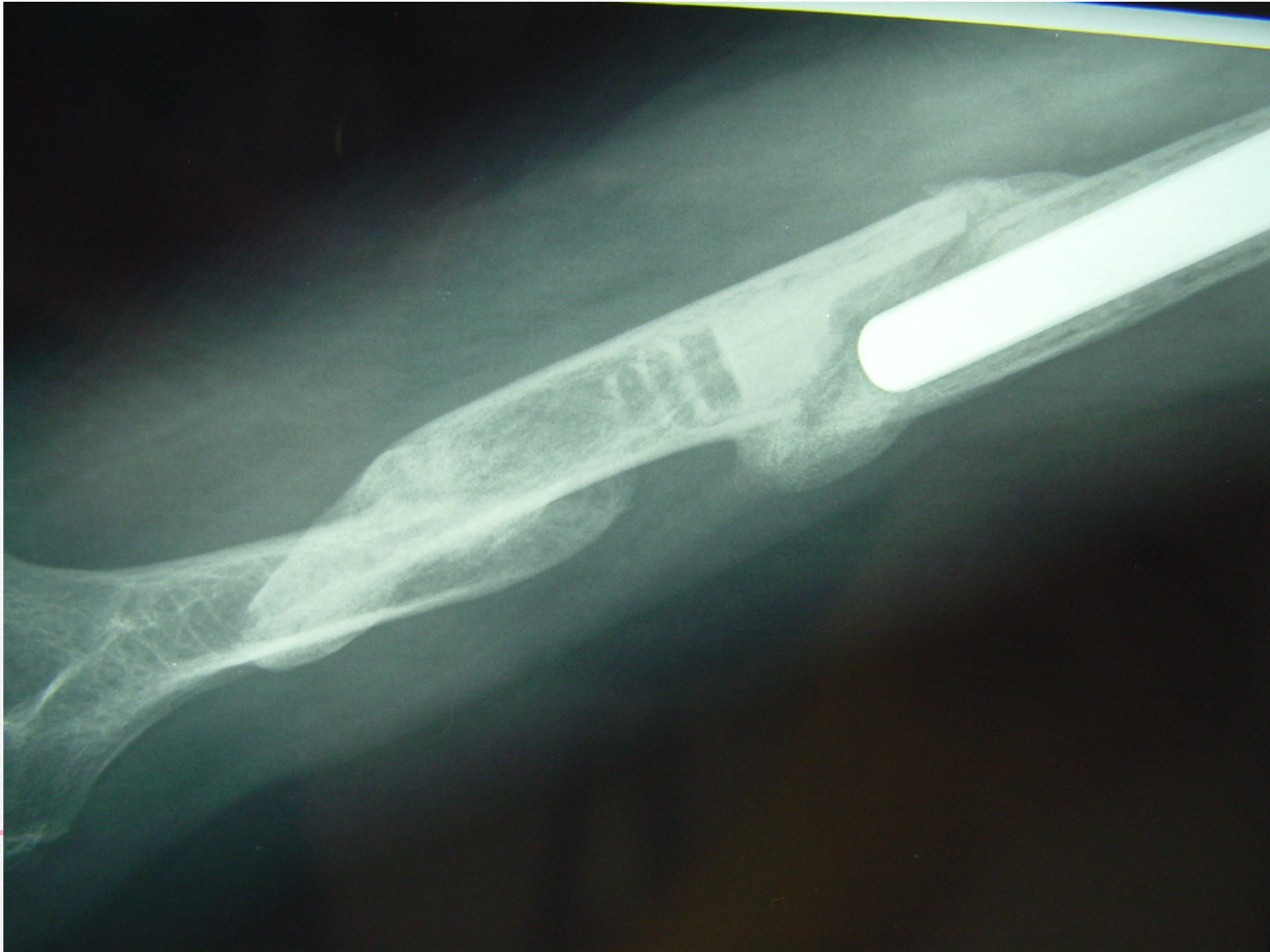Humerus_antero-posterior_Standard_MEDIUM ADULT_Factory4 Pr
antero-posterior Both
CROPPED Reduce Size
WW: 4554 WC: 5862 Zoom=70%

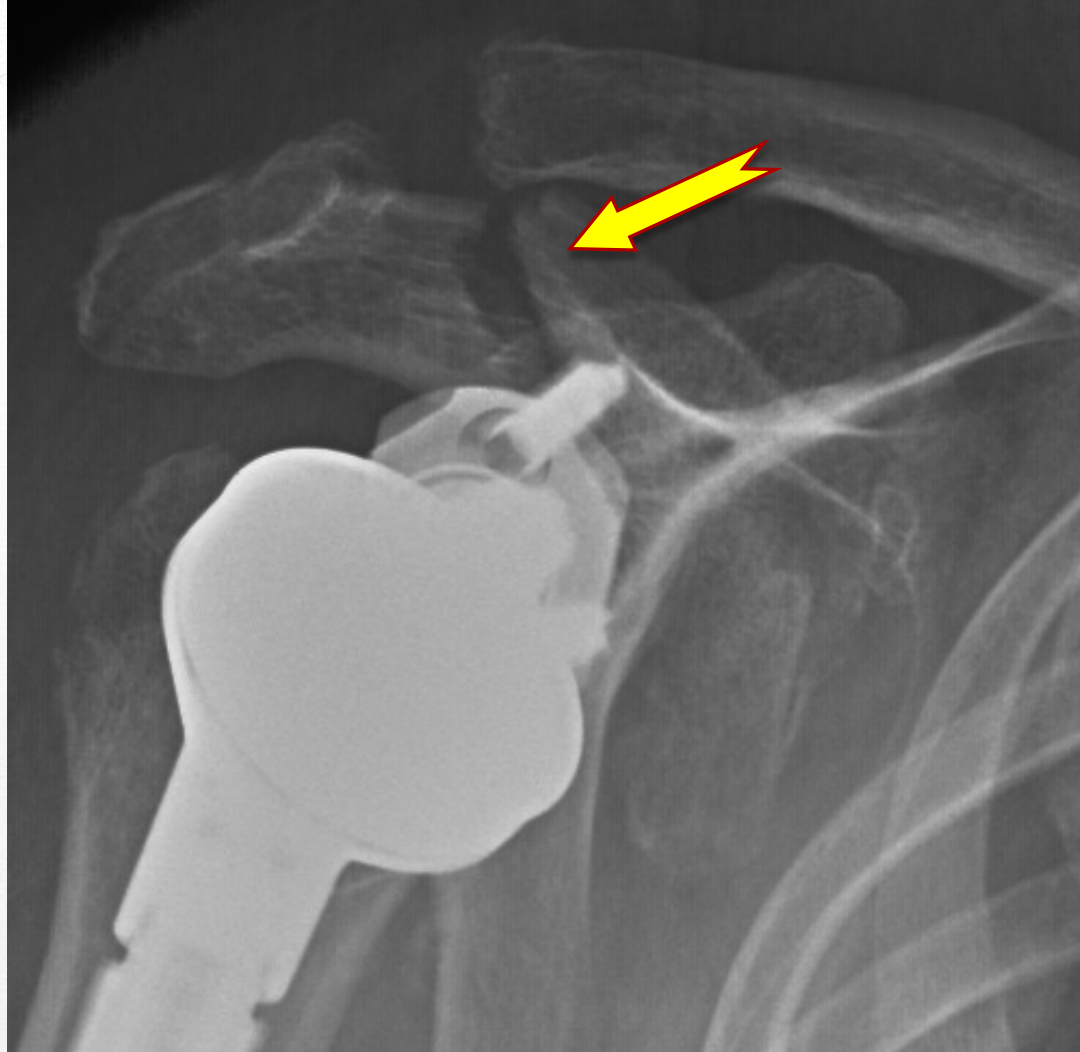Humerus_antero-posterior_Standard_MEDIUM ADULT_Factory4 Pr
antero-posterior Both
CROPPED Reduce Size
WW: 4578 WC: 5876 Zoom=70%

Postoperative fractures



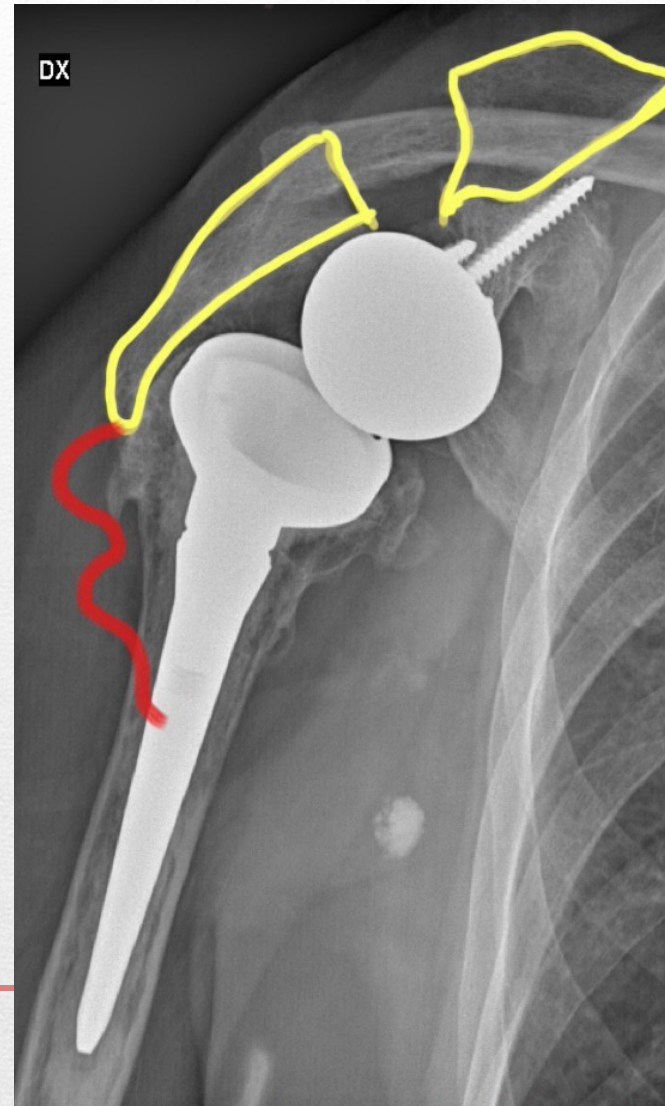
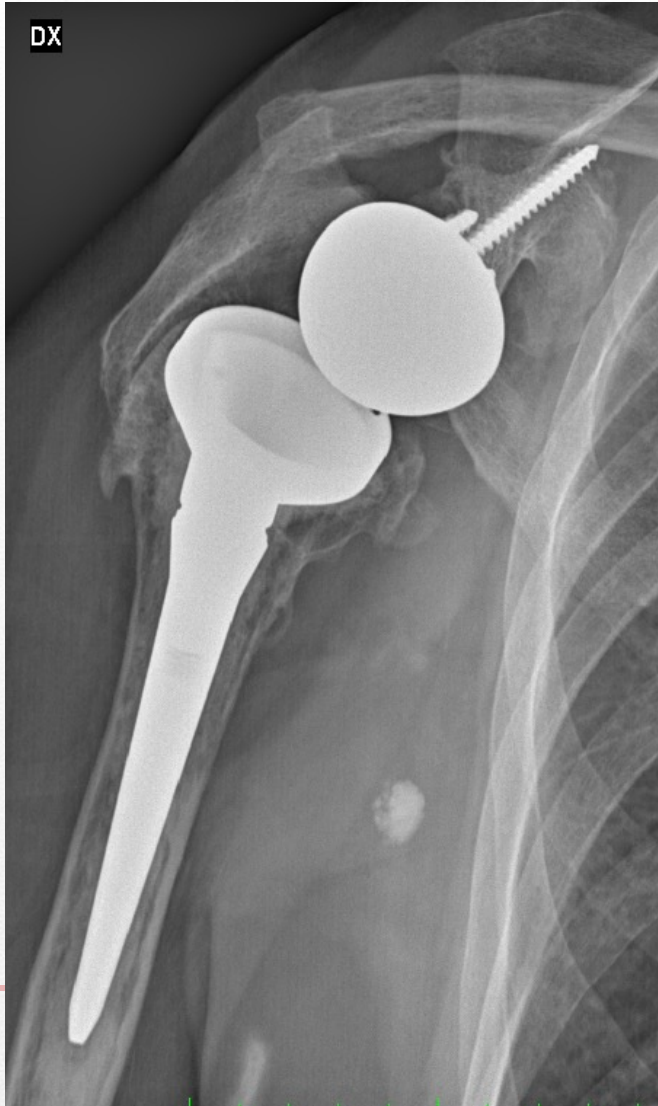





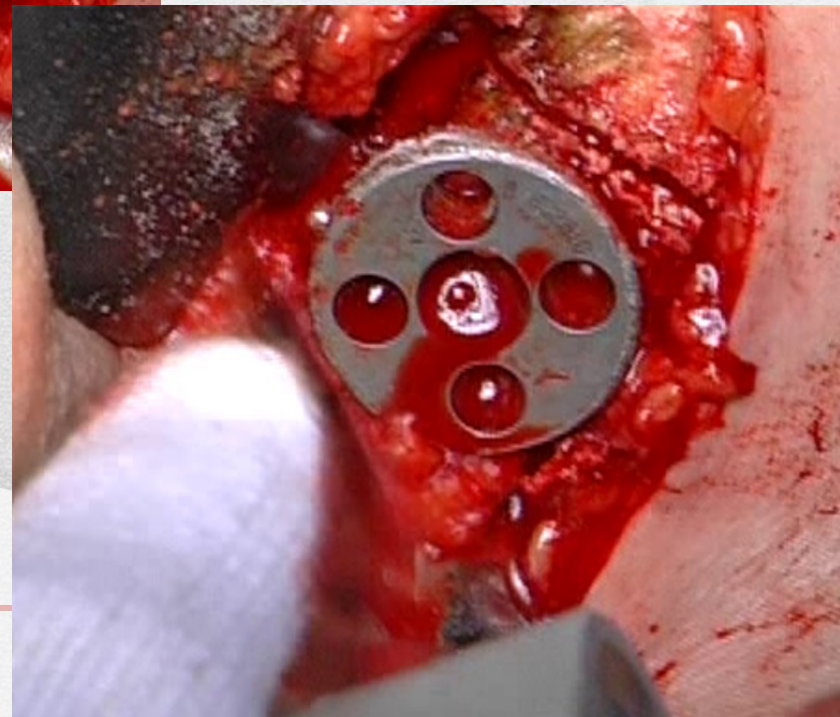
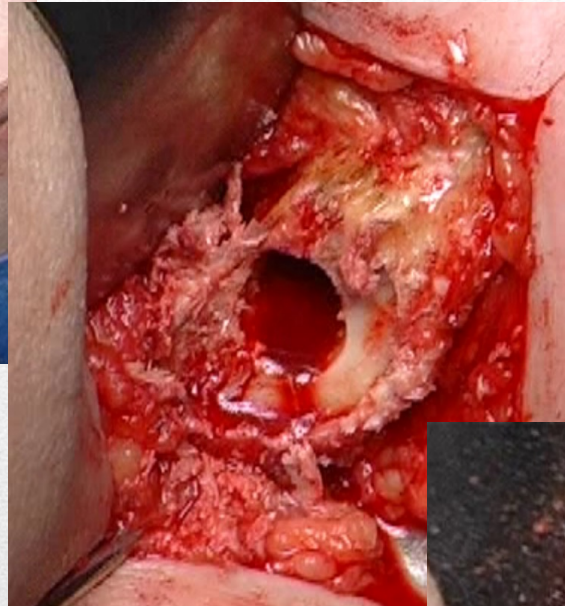
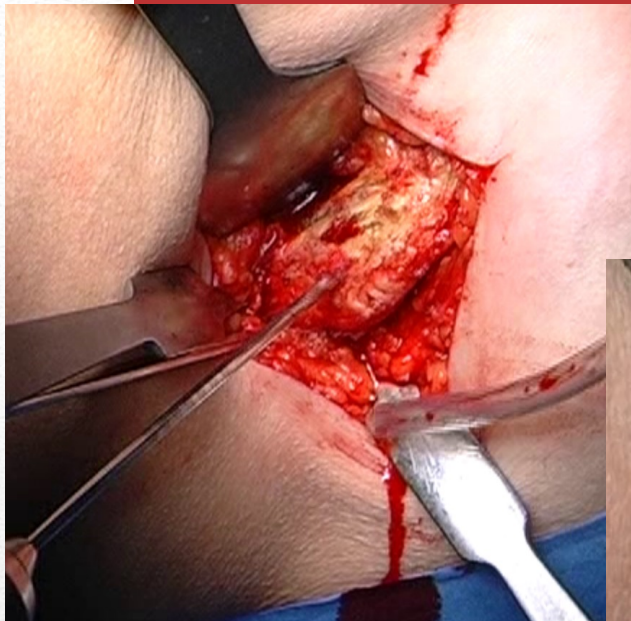
Scapula spine fracture

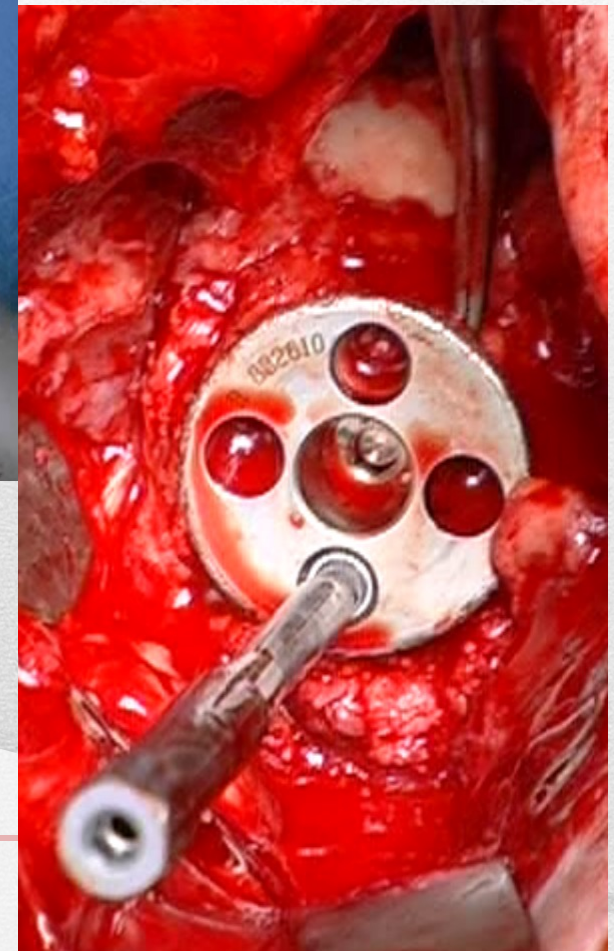
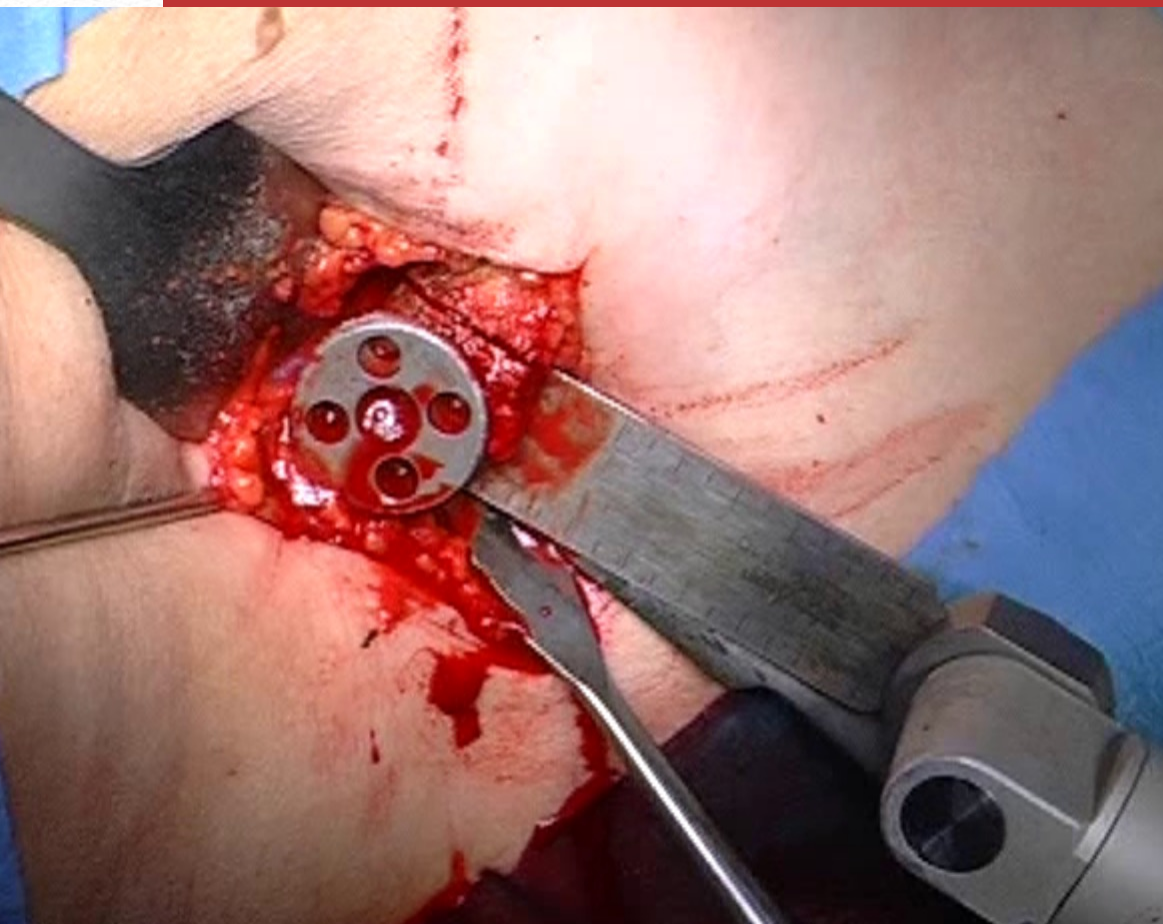
Scapula fracture? Basi-acromion?

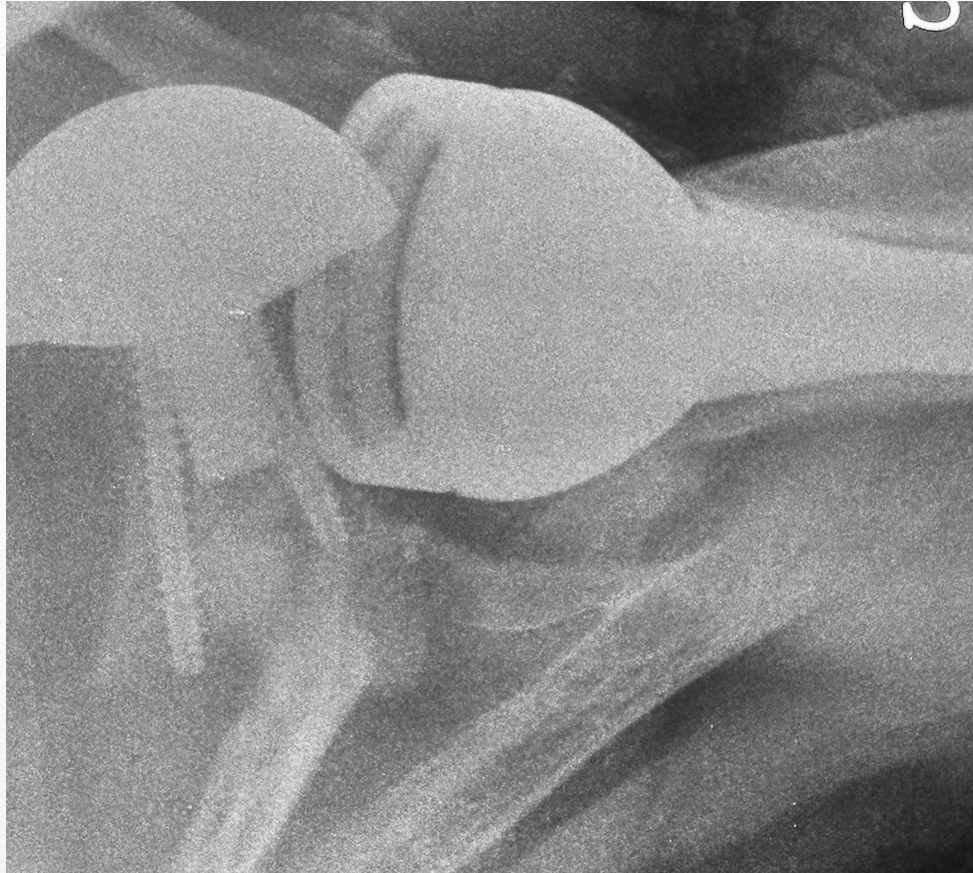




GE.CO.TEAM



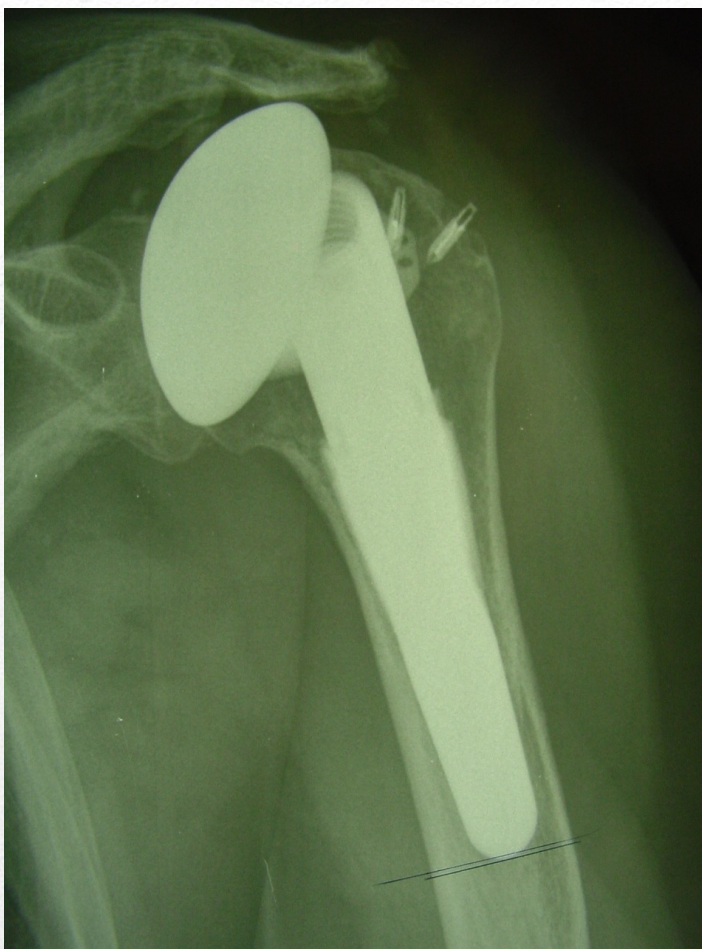



Rheumatoid arthritis

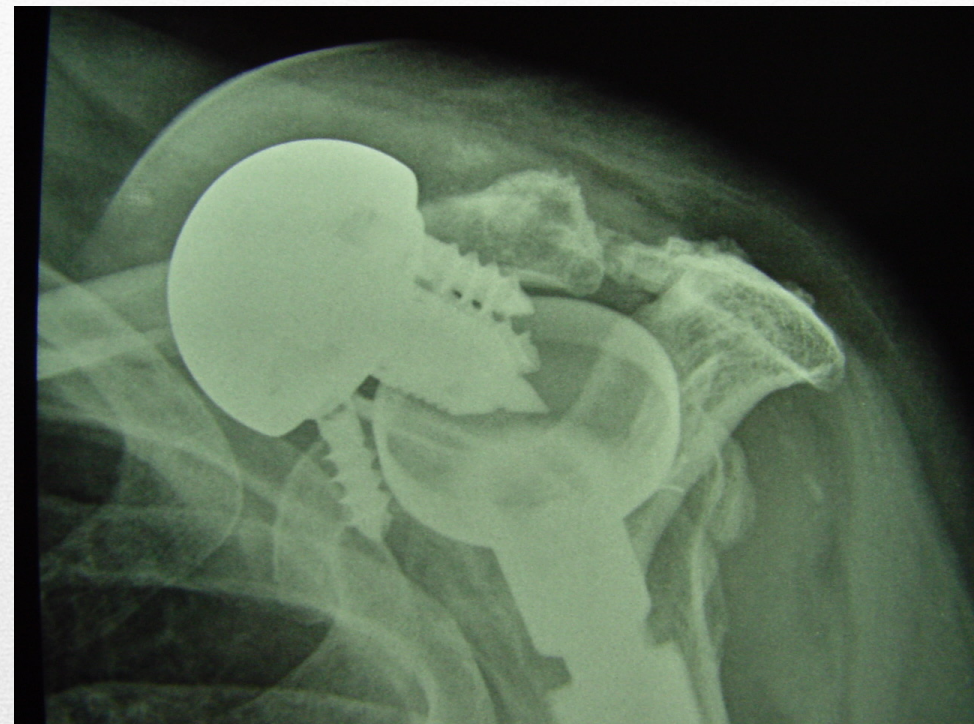
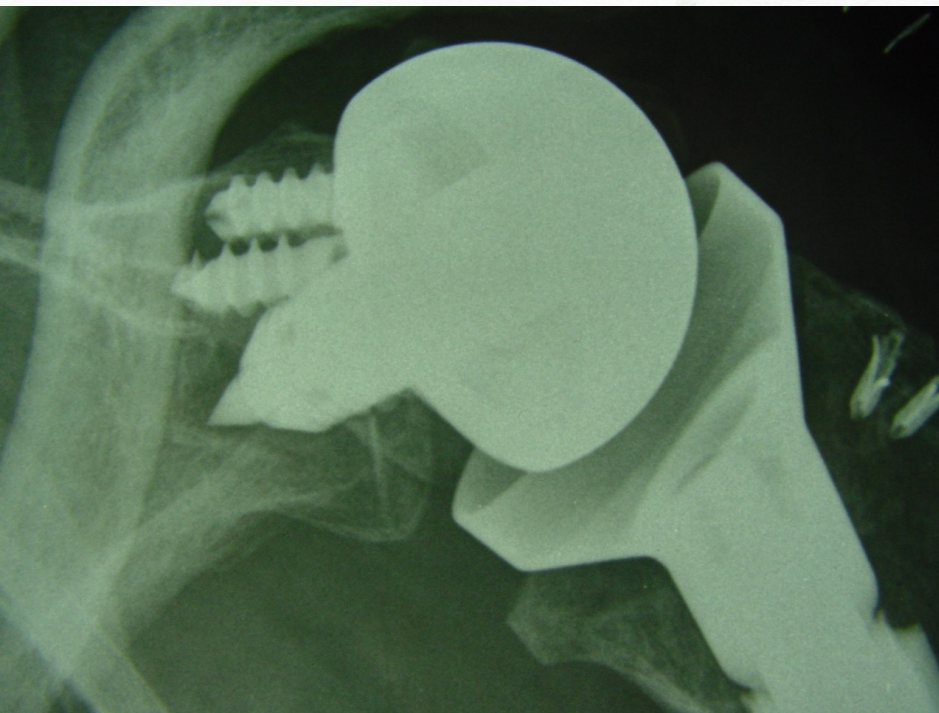

CUFF REPAIR TO ANATOMICAL TO REVERSE

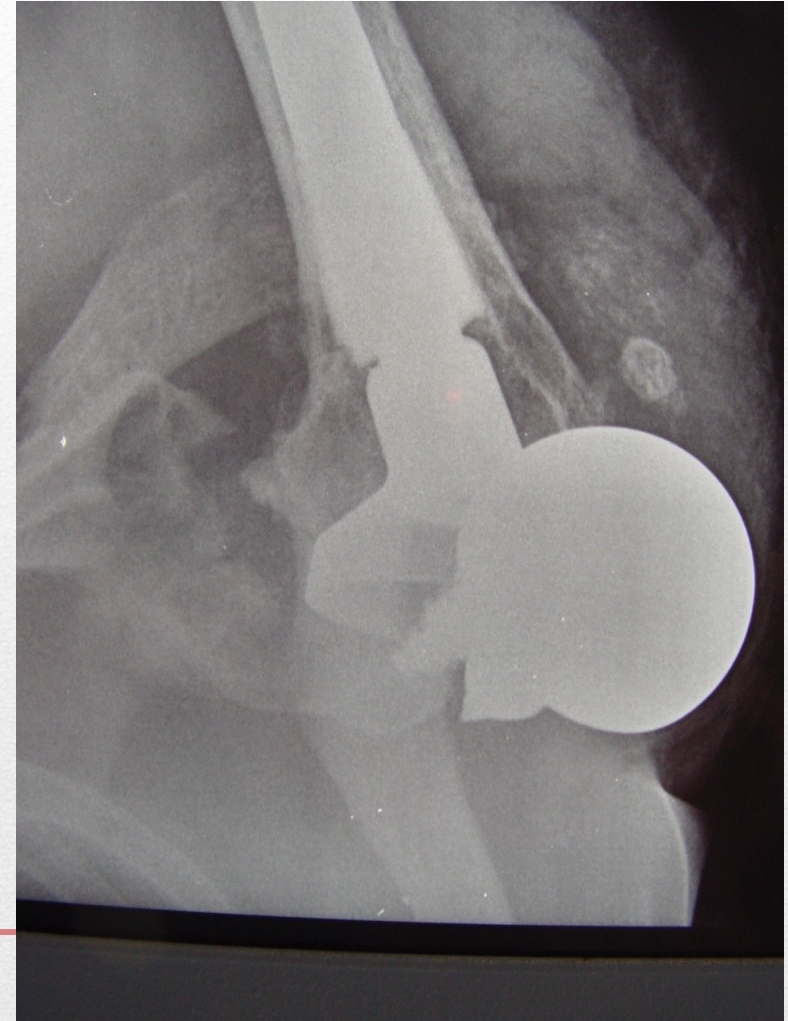
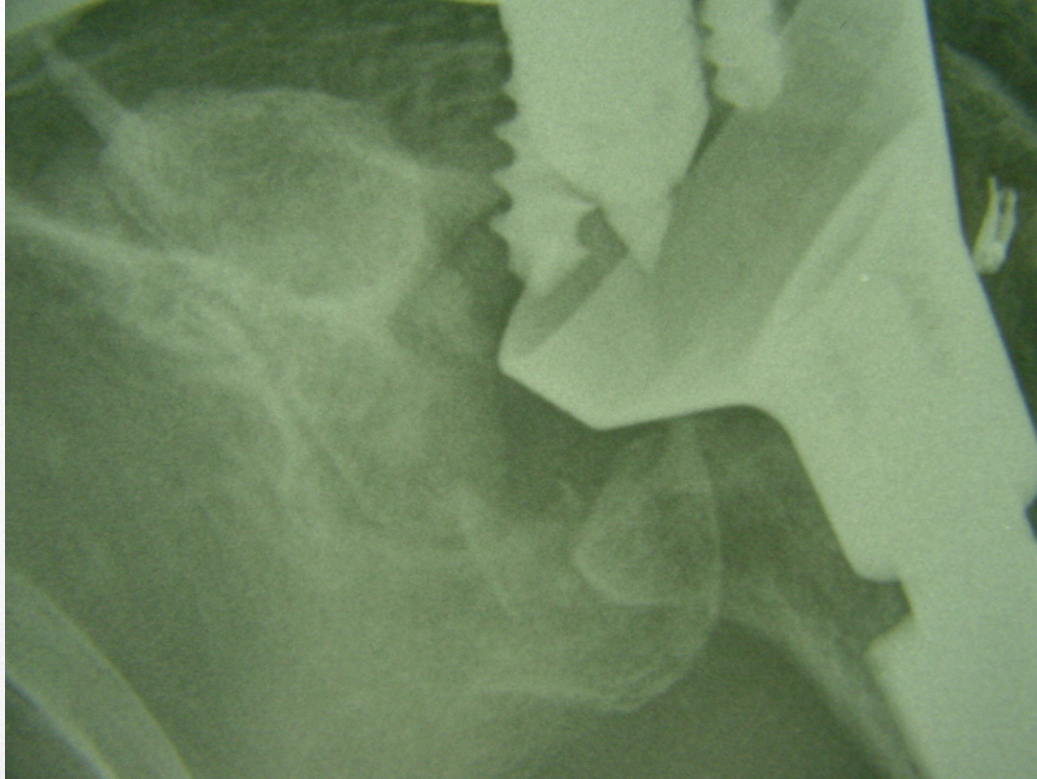


**Hemi for cuff tear
arthropathy**

The bad tilt



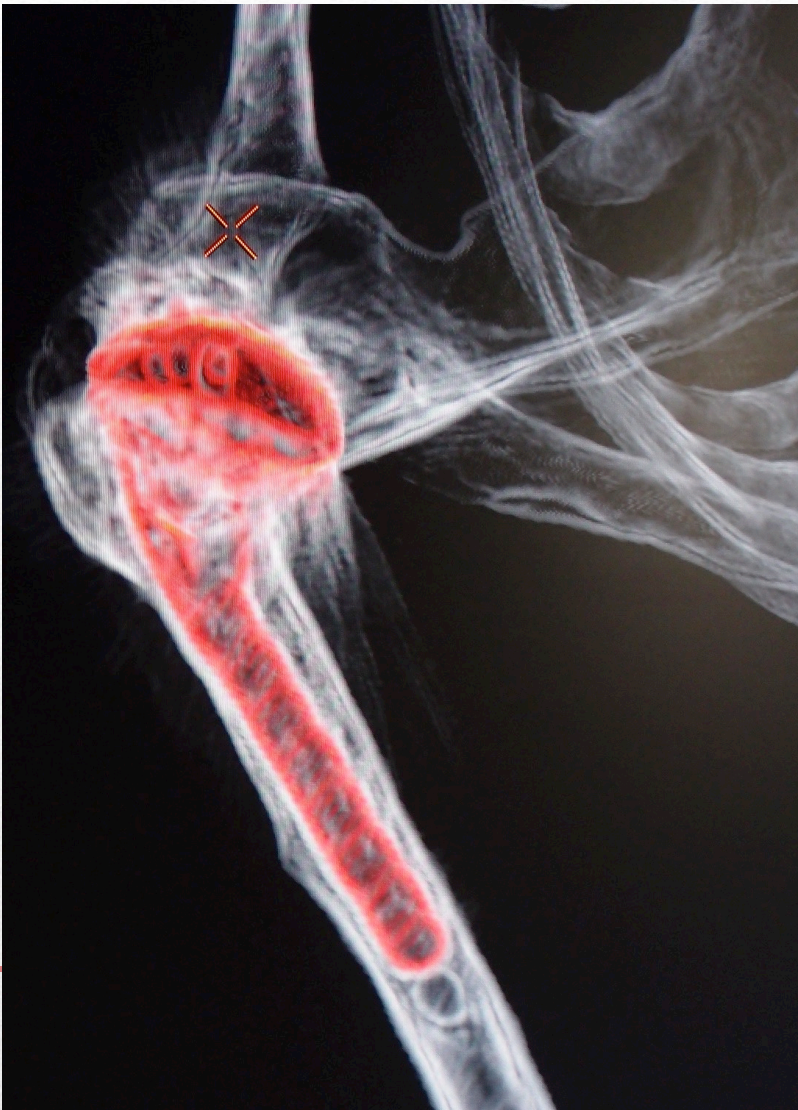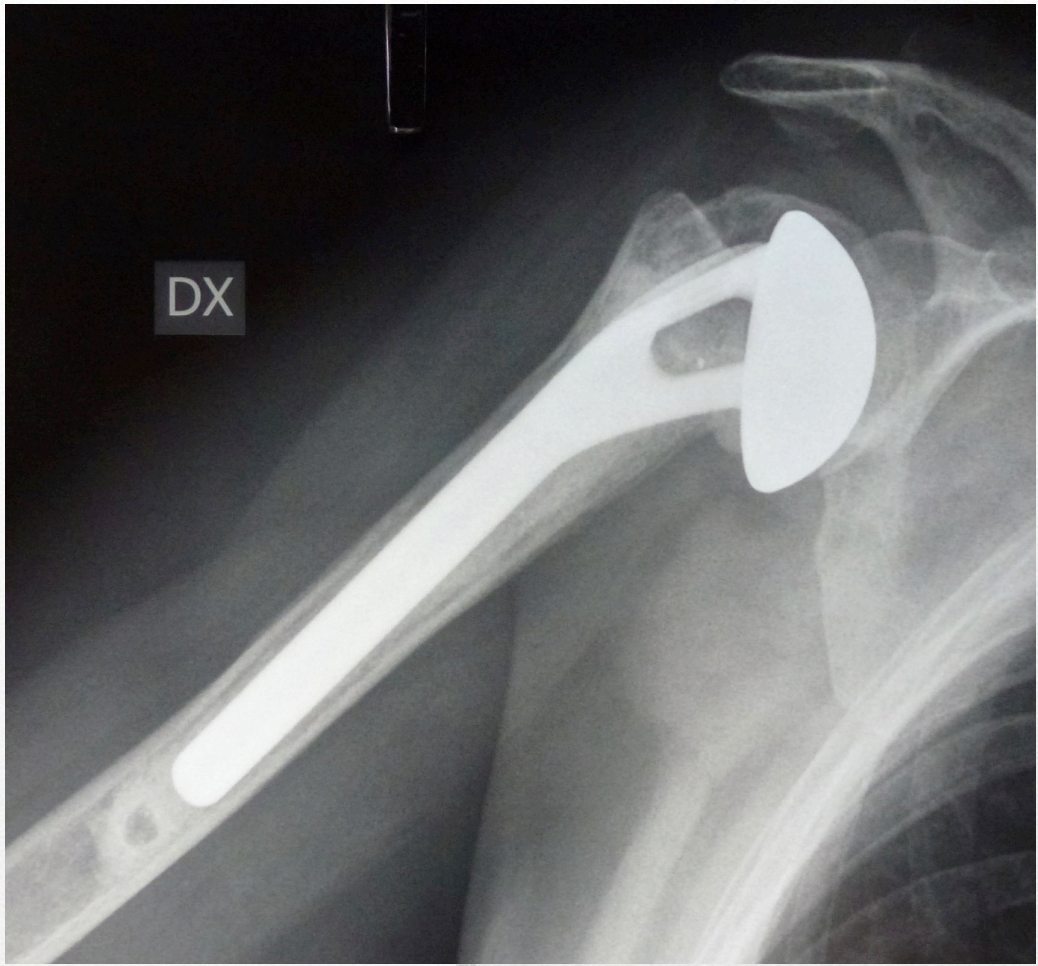
Demanding revision

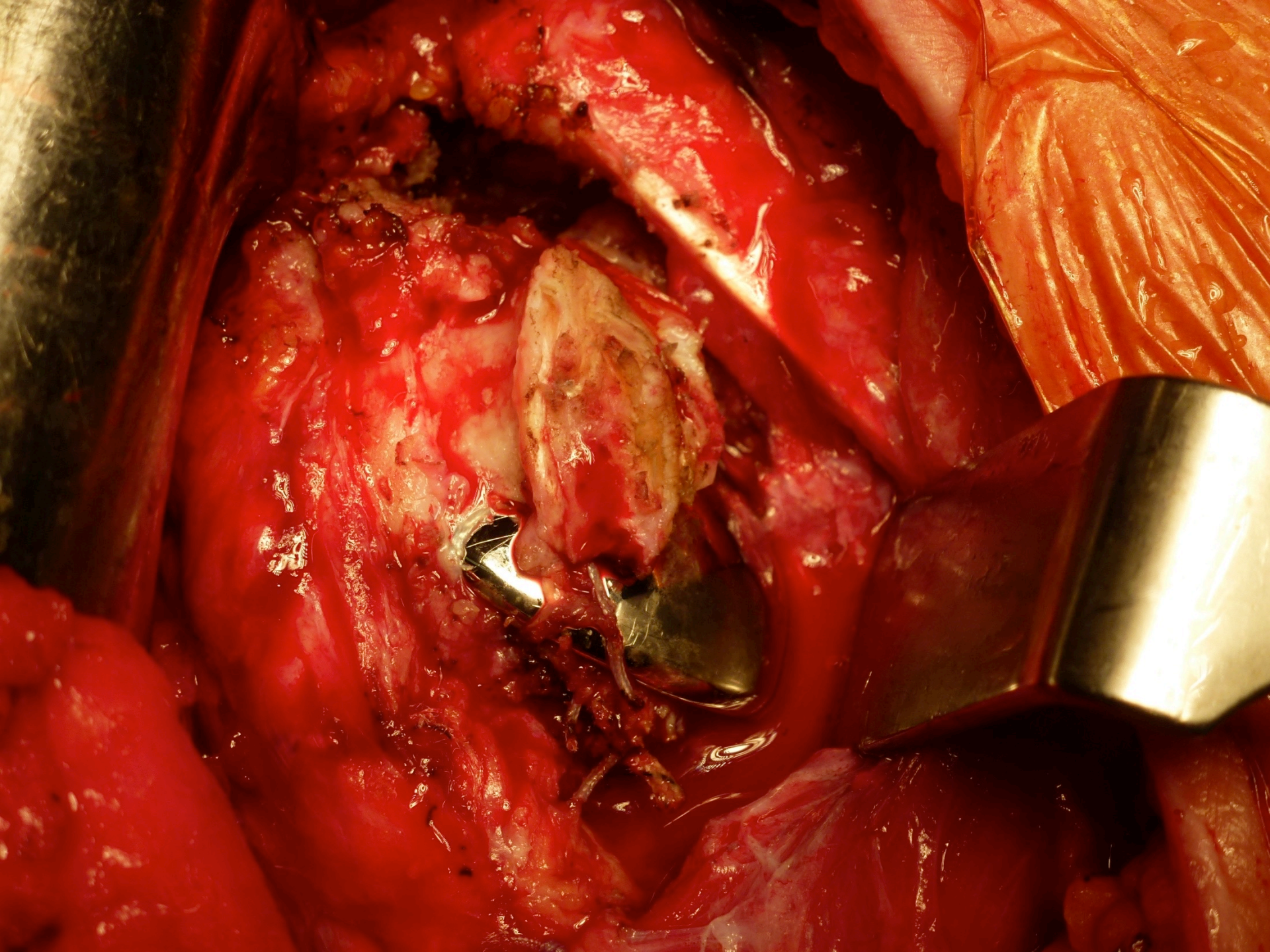




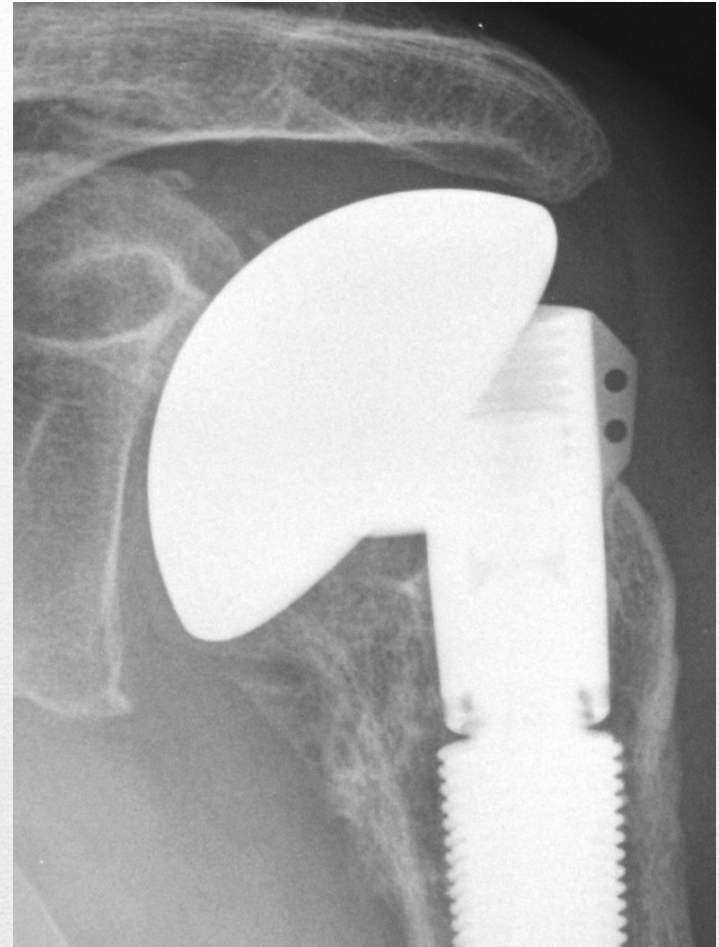
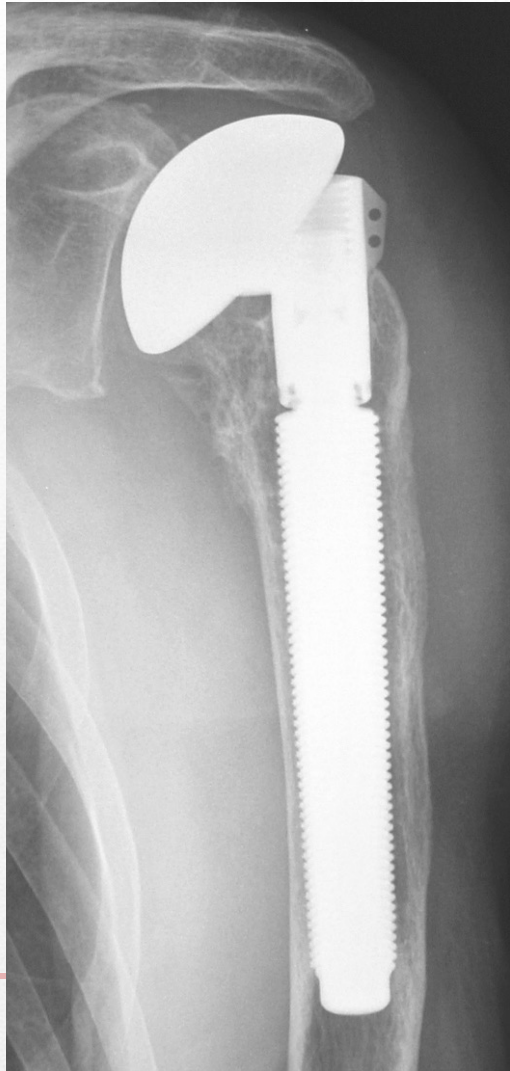GLI STELI DANNATI

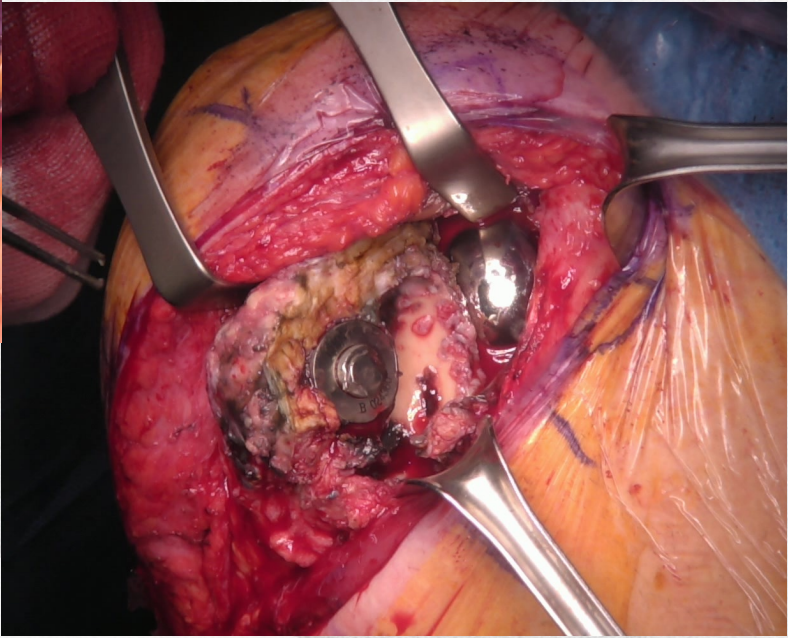
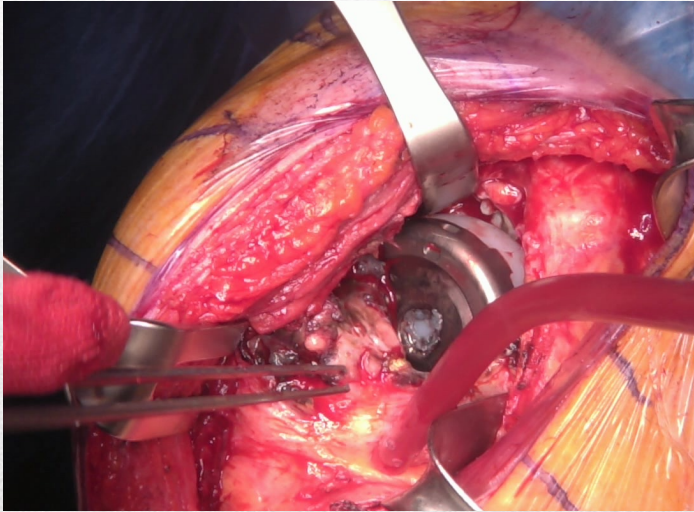
DX

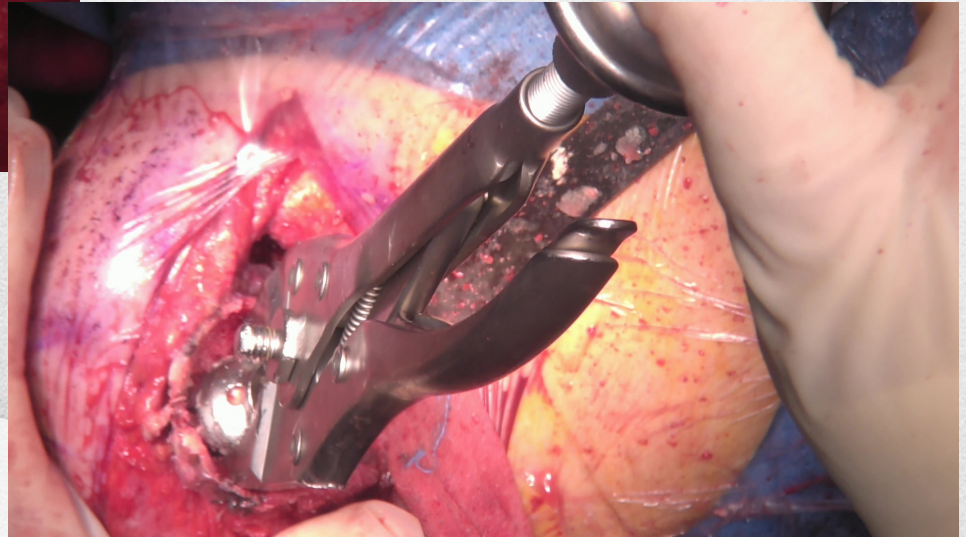
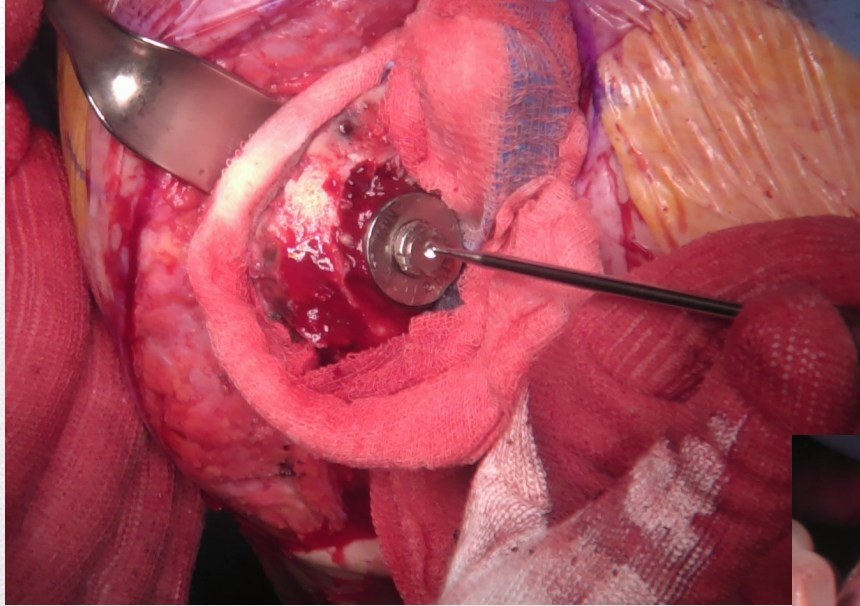


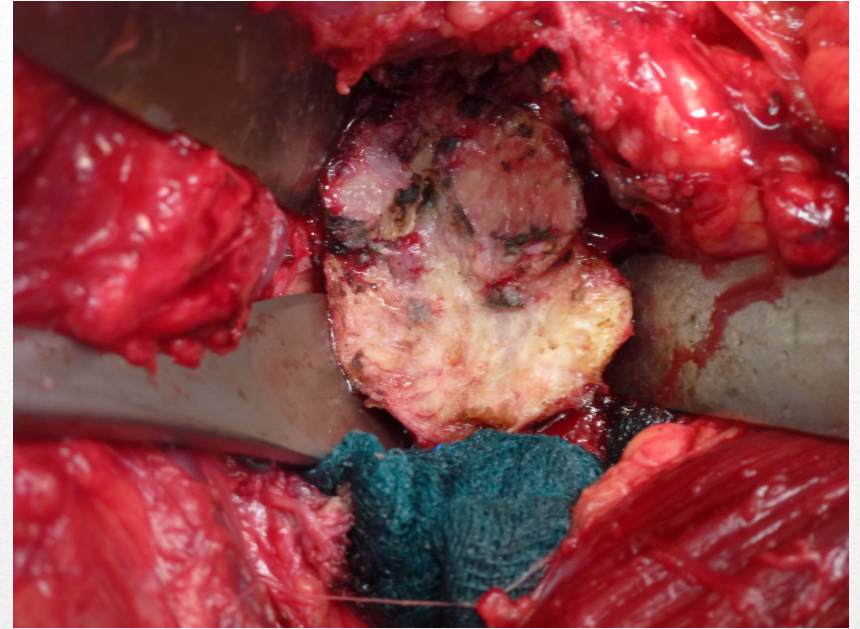
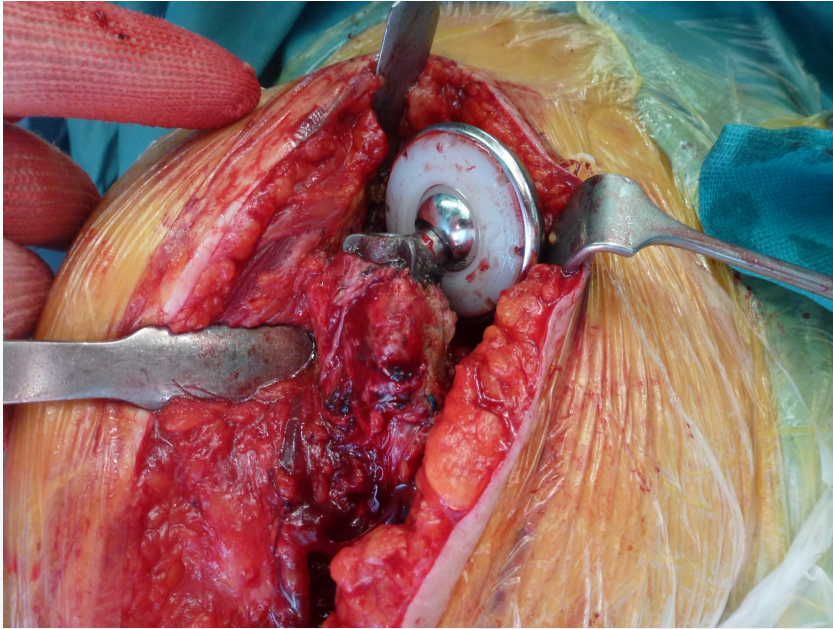


Hard to be revised, old generation stem





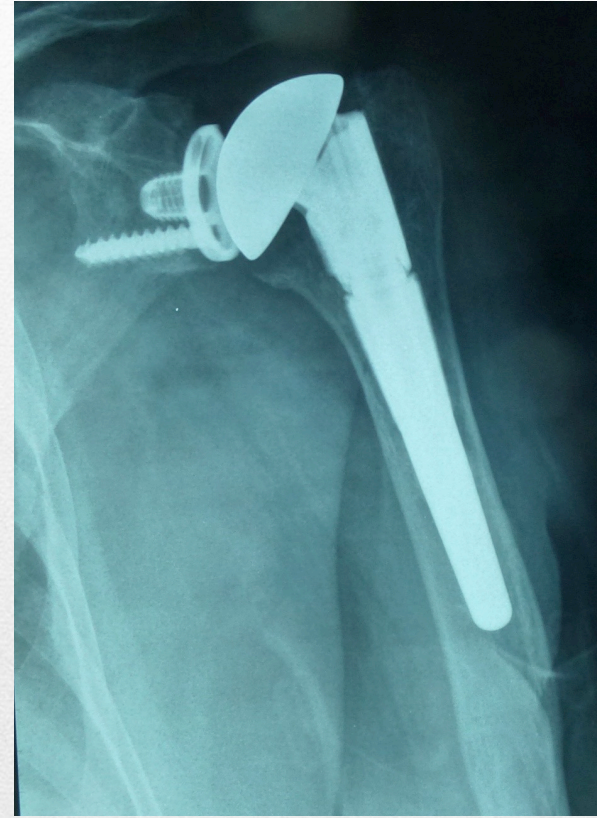
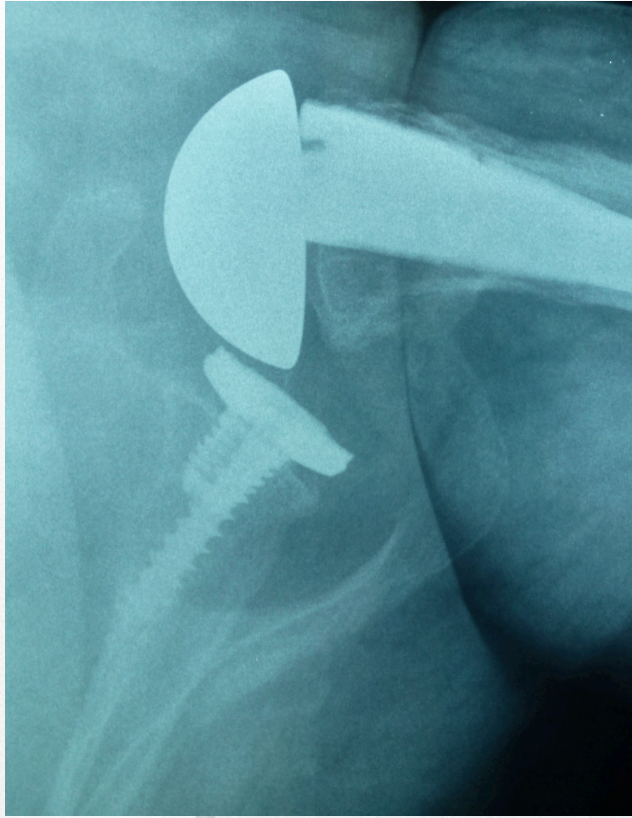




Bi-polar: does it help ?

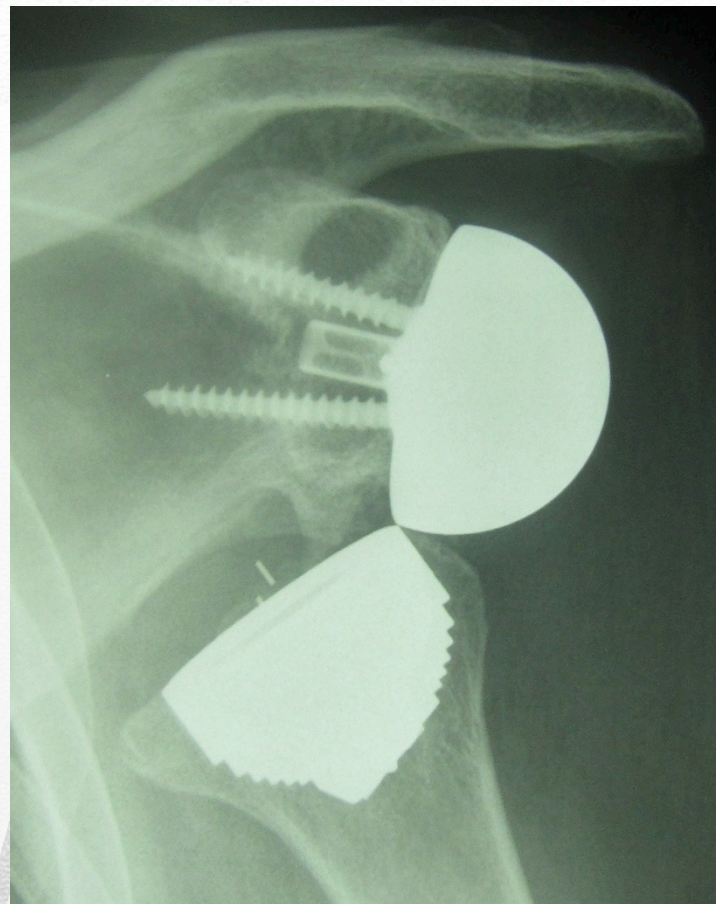
The background features a large, dark red geometric shape in the upper left, with a lighter red gradient extending from its bottom edge. The rest of the background is white, with faint, light gray geometric lines and shapes. A thin, dark red horizontal line is positioned near the bottom of the page.

INSTABILITY



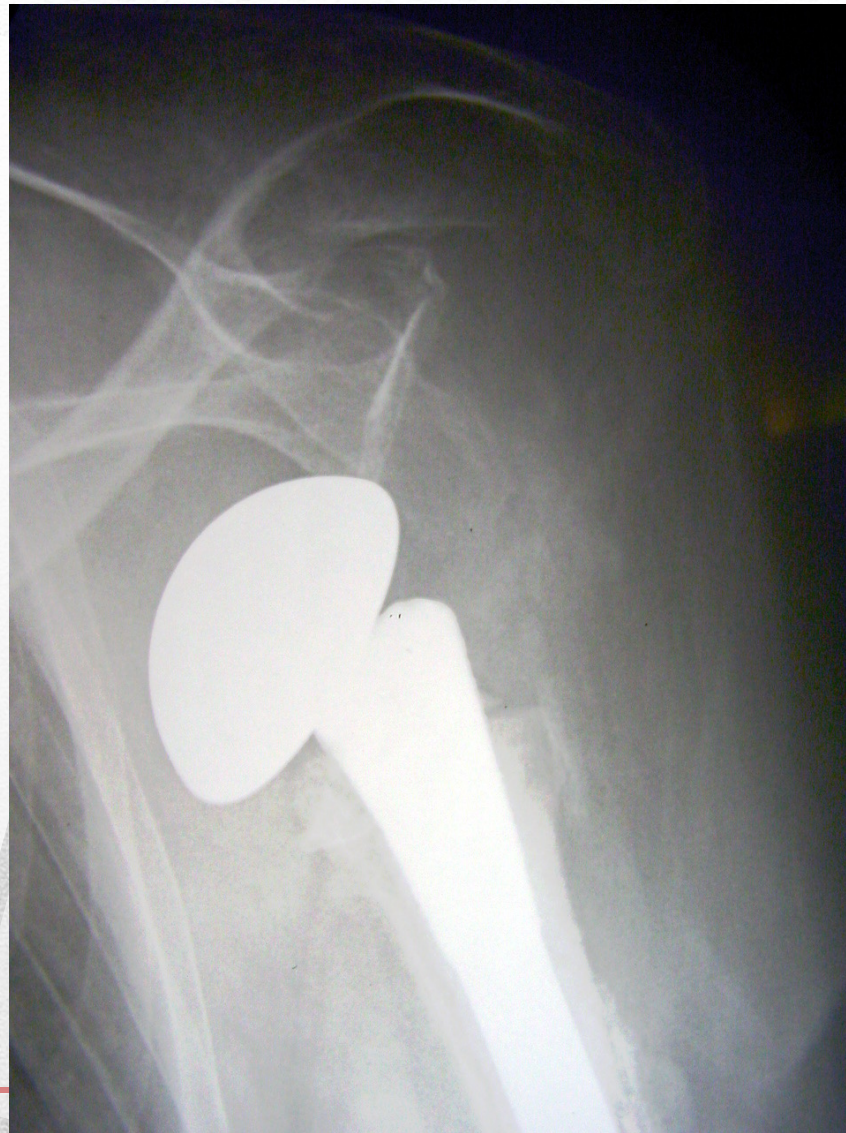

GE.CO.TEAM

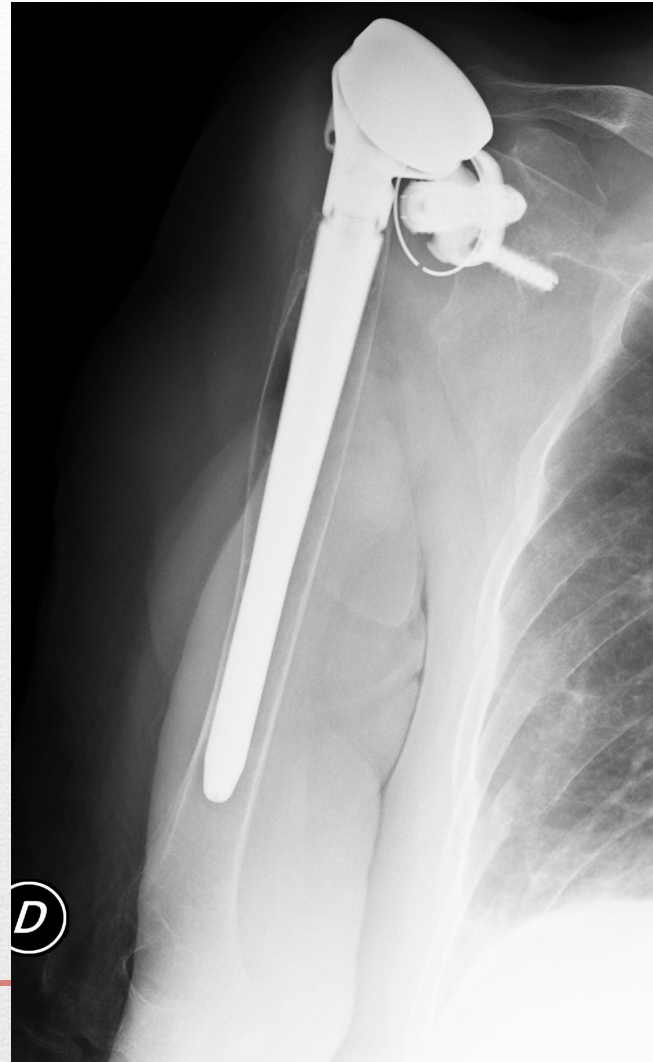
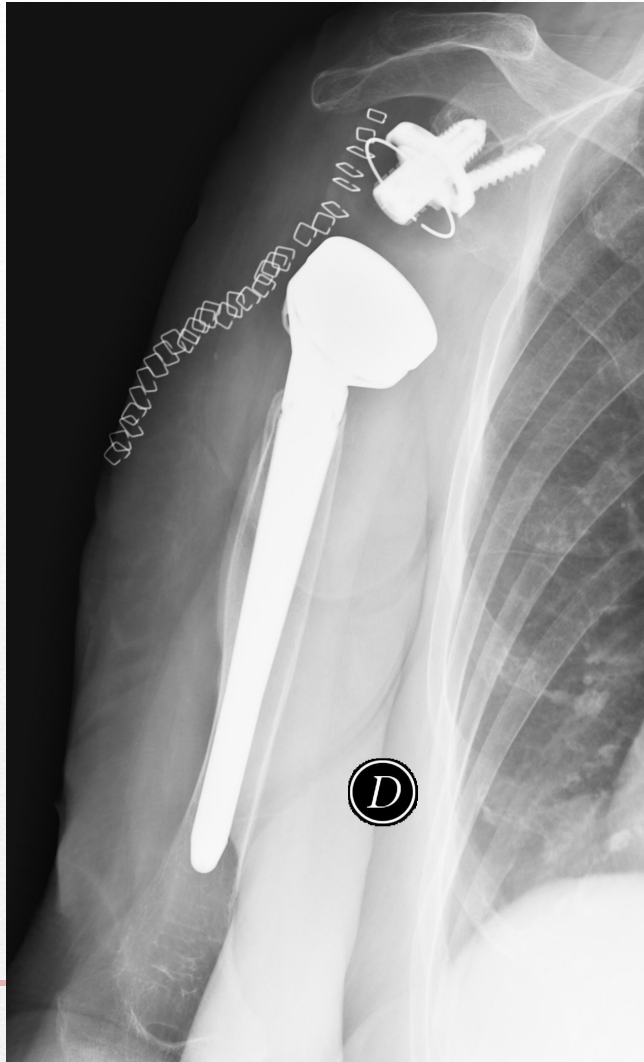


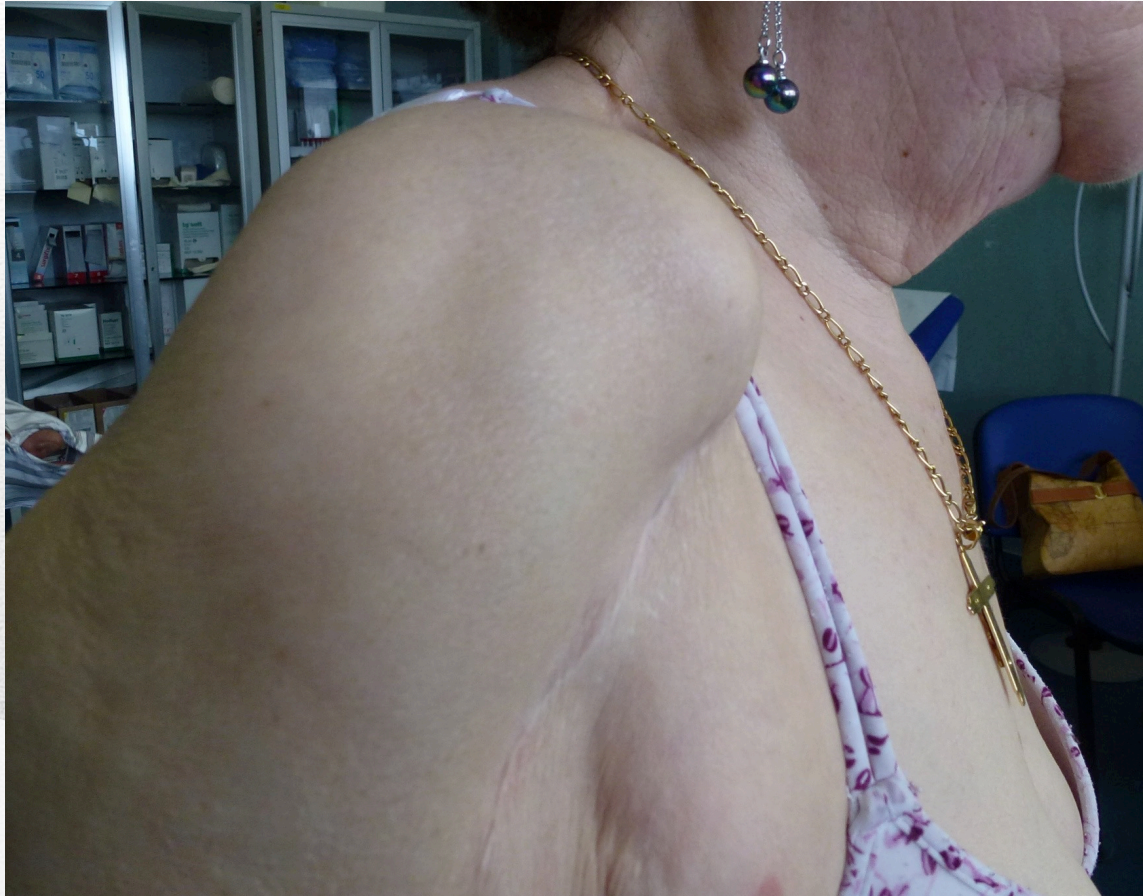Humeral dislocation

Loose tuberosities, loose implant

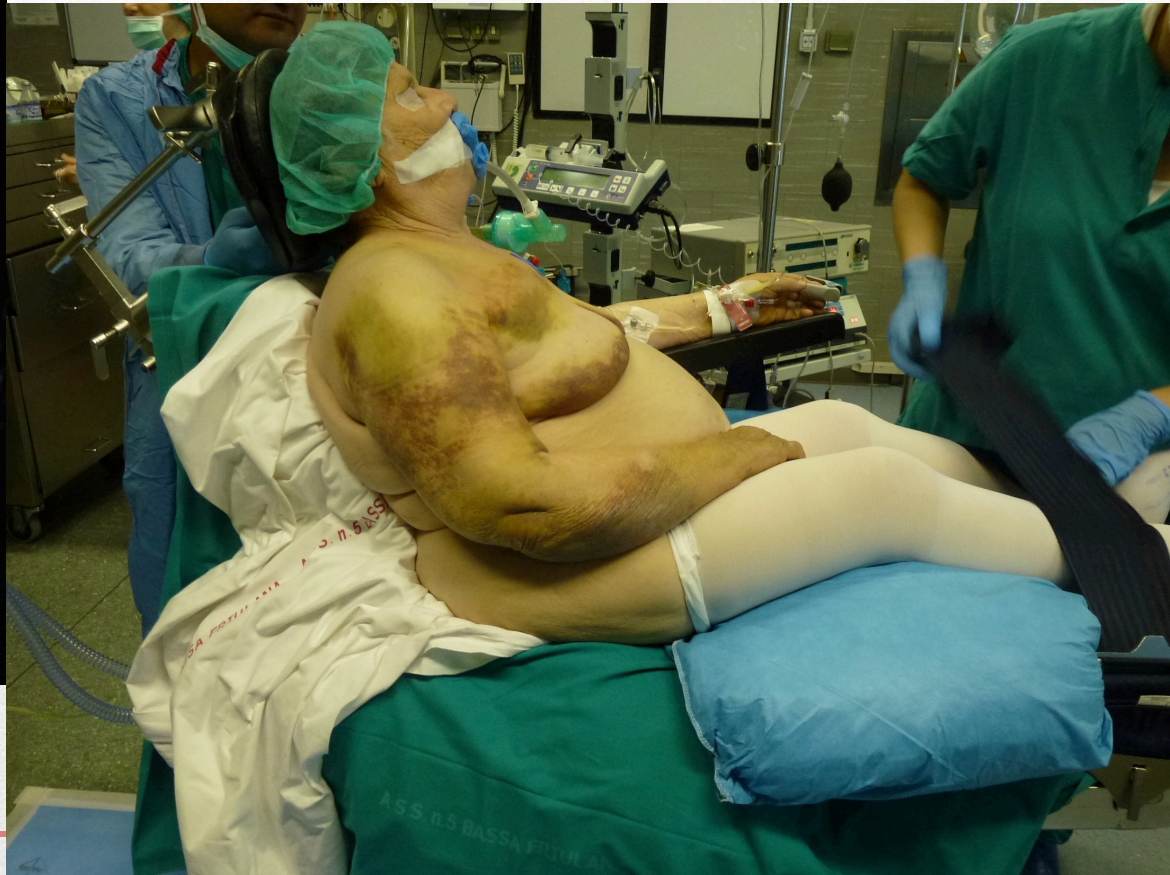
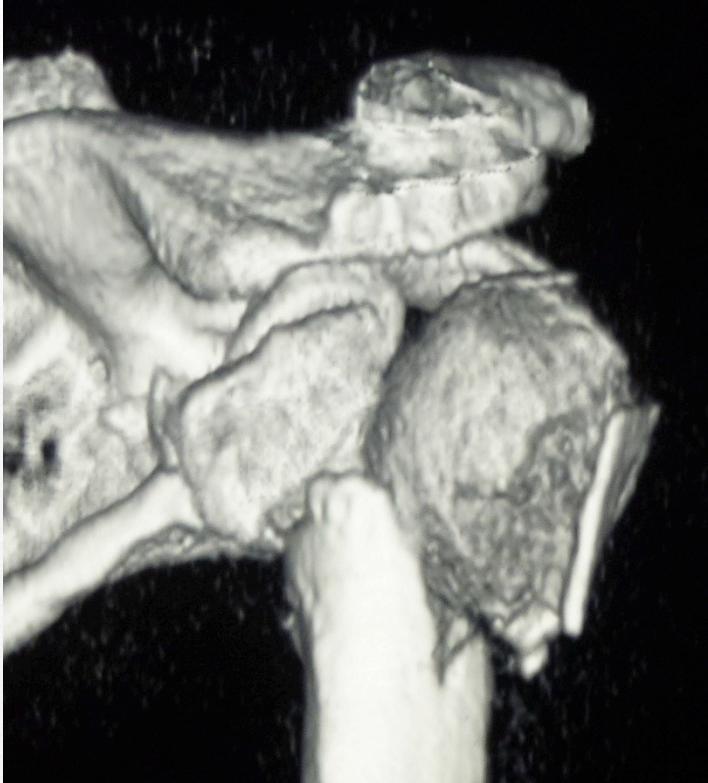
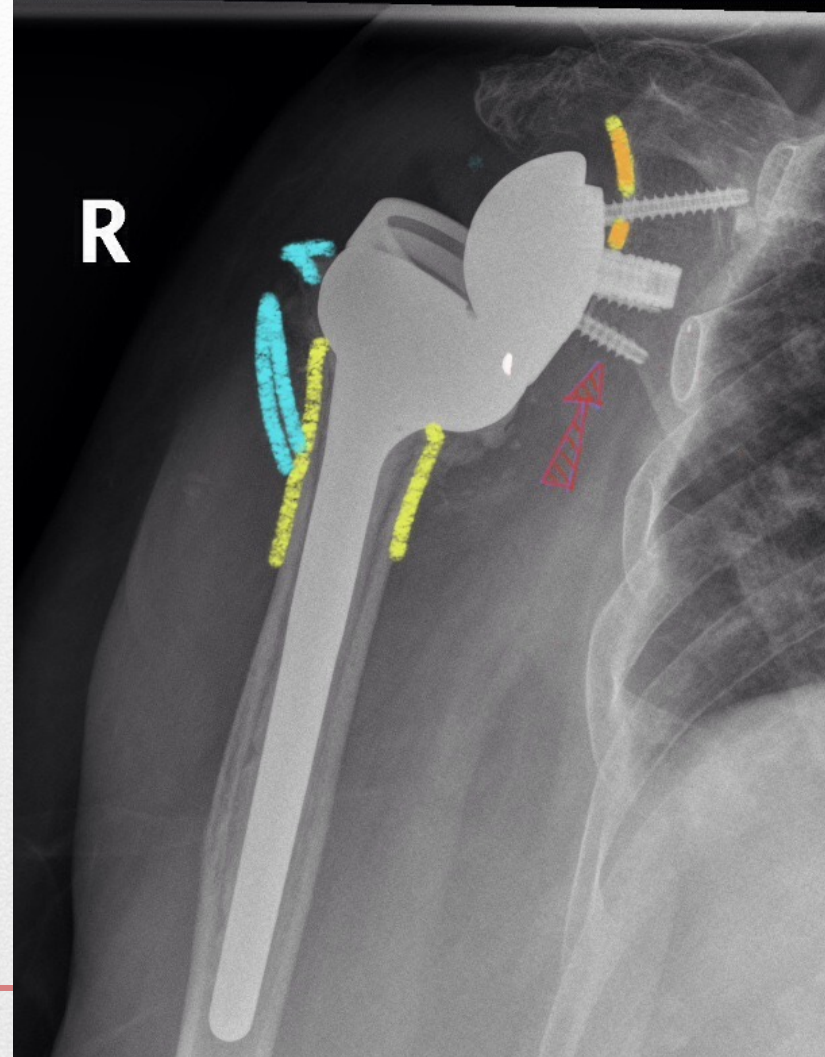
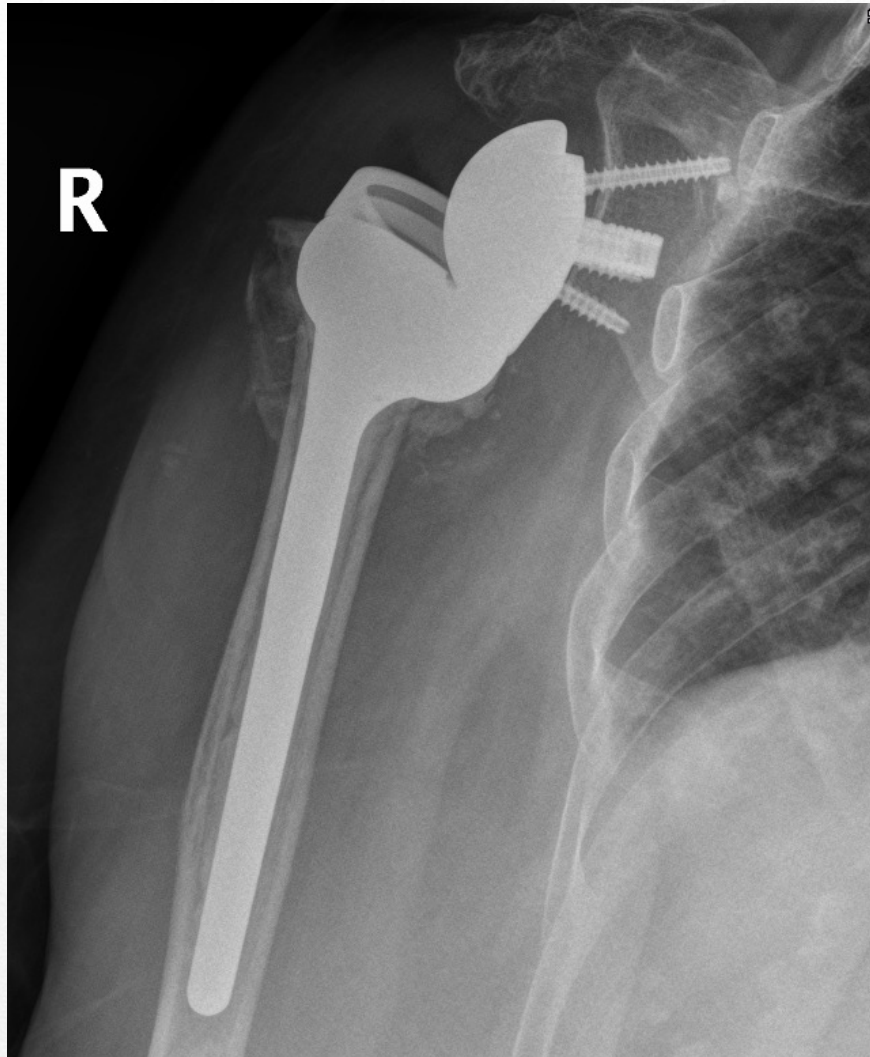
Loose implant

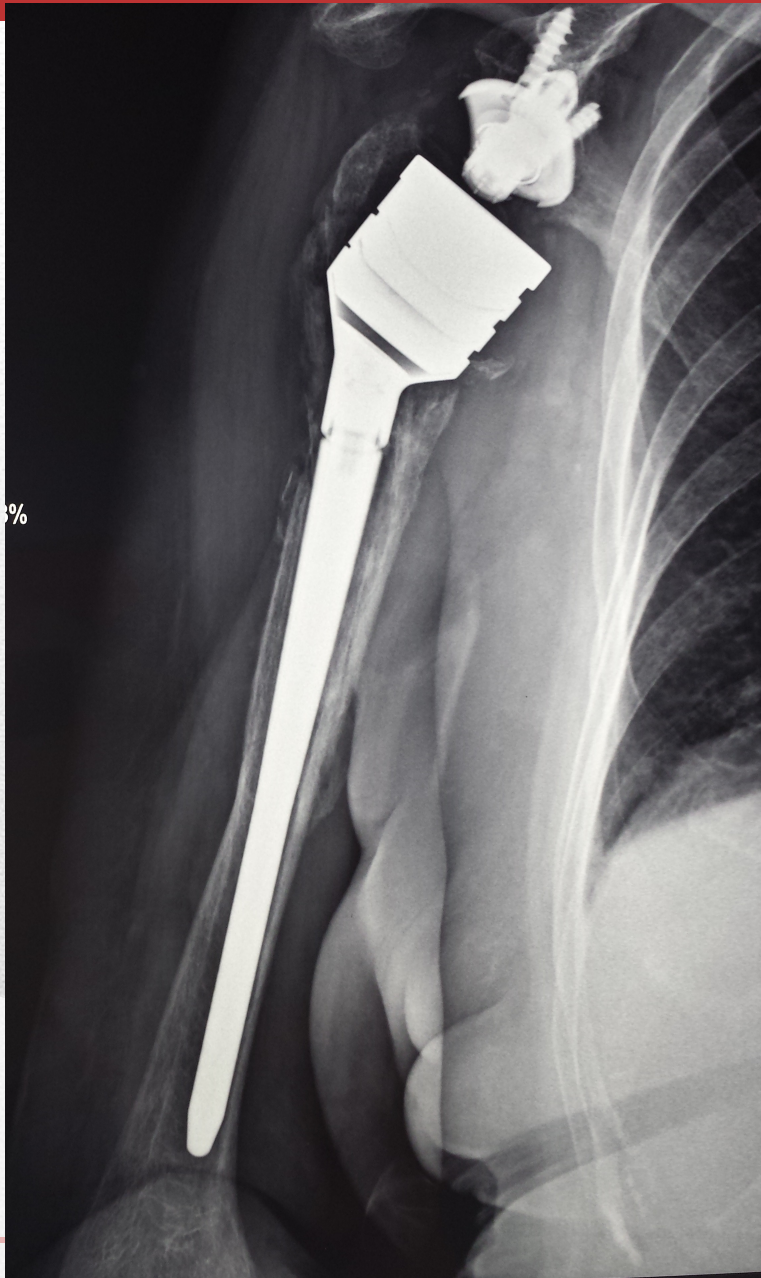



Care to large breast women!

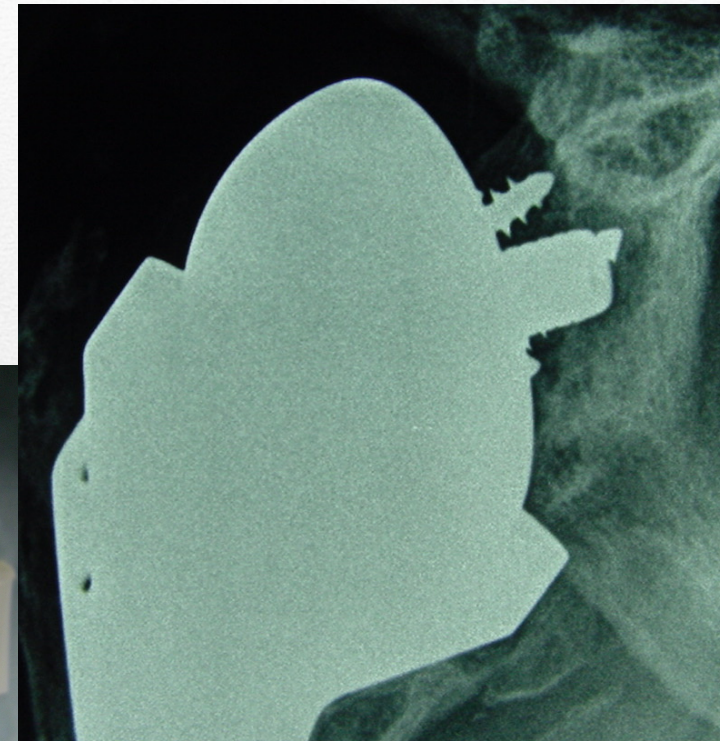
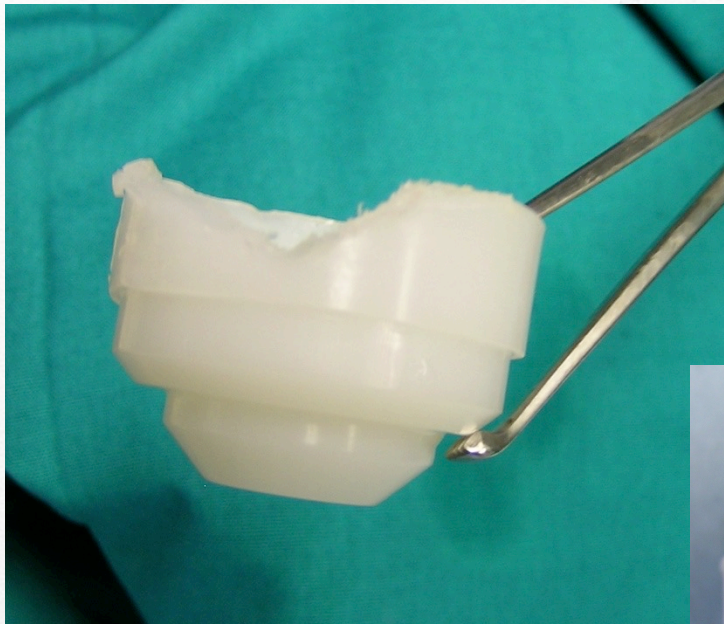






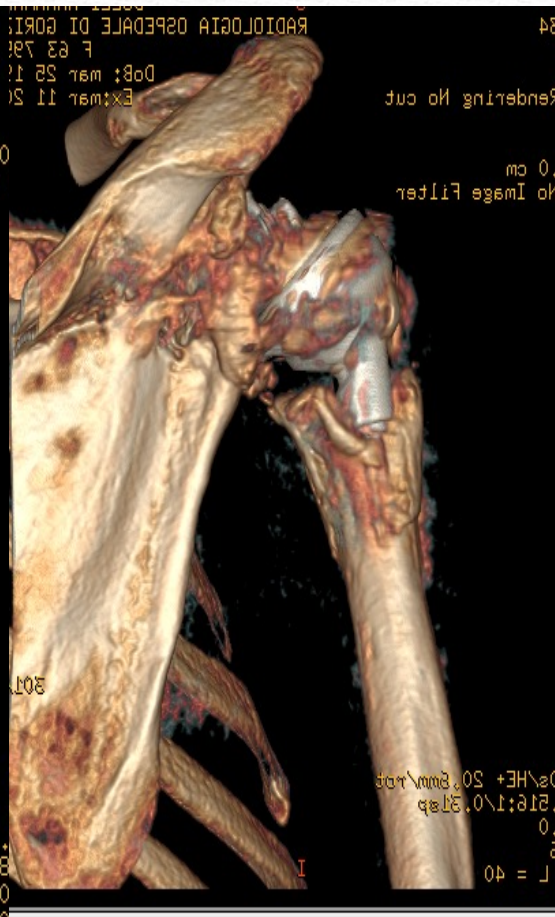
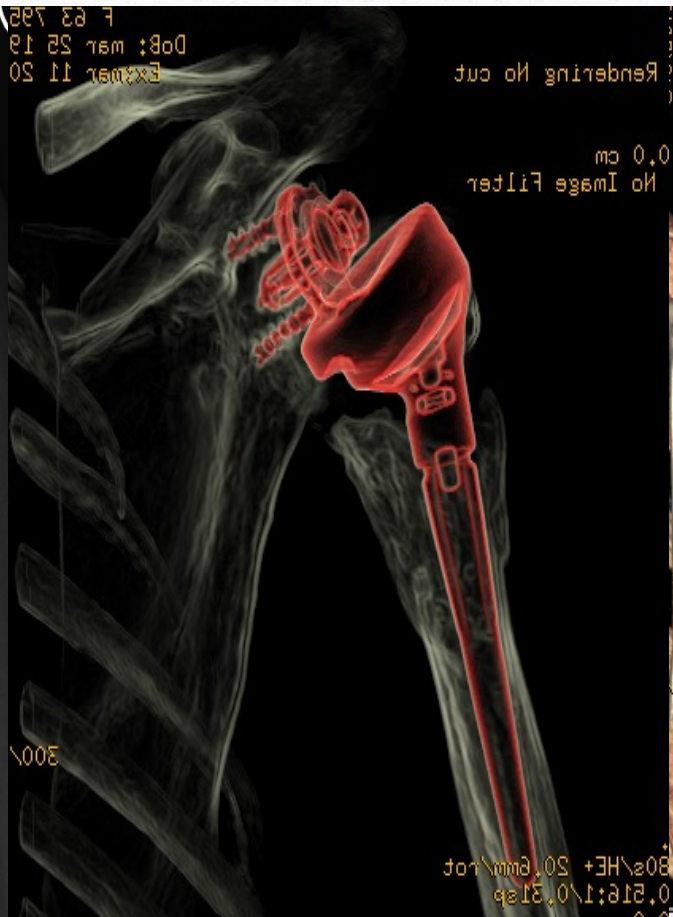
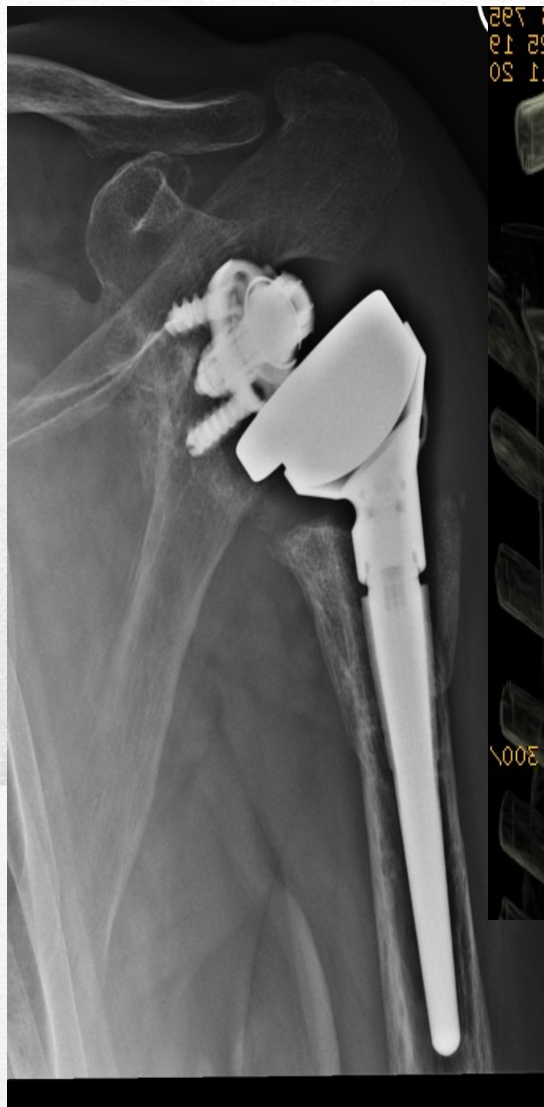Costrained polyethylene


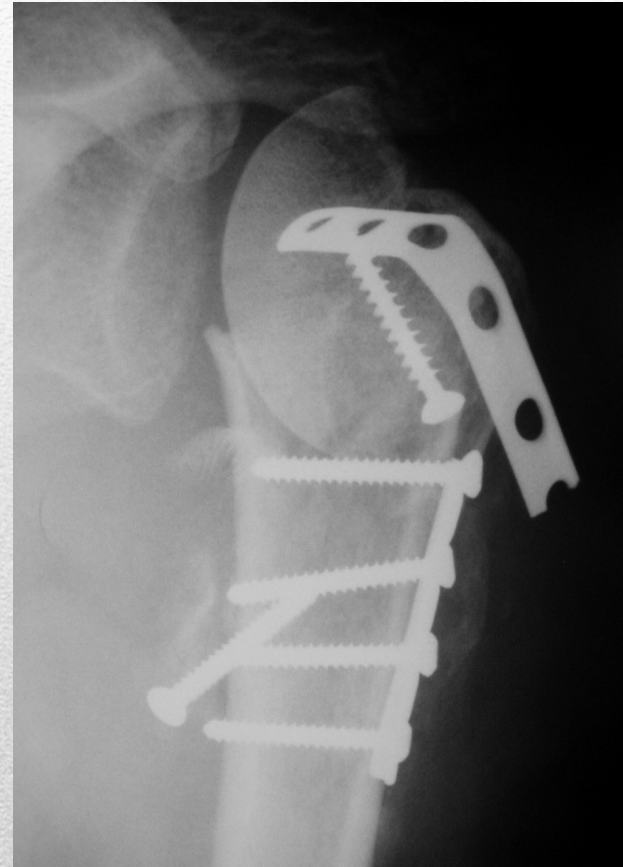
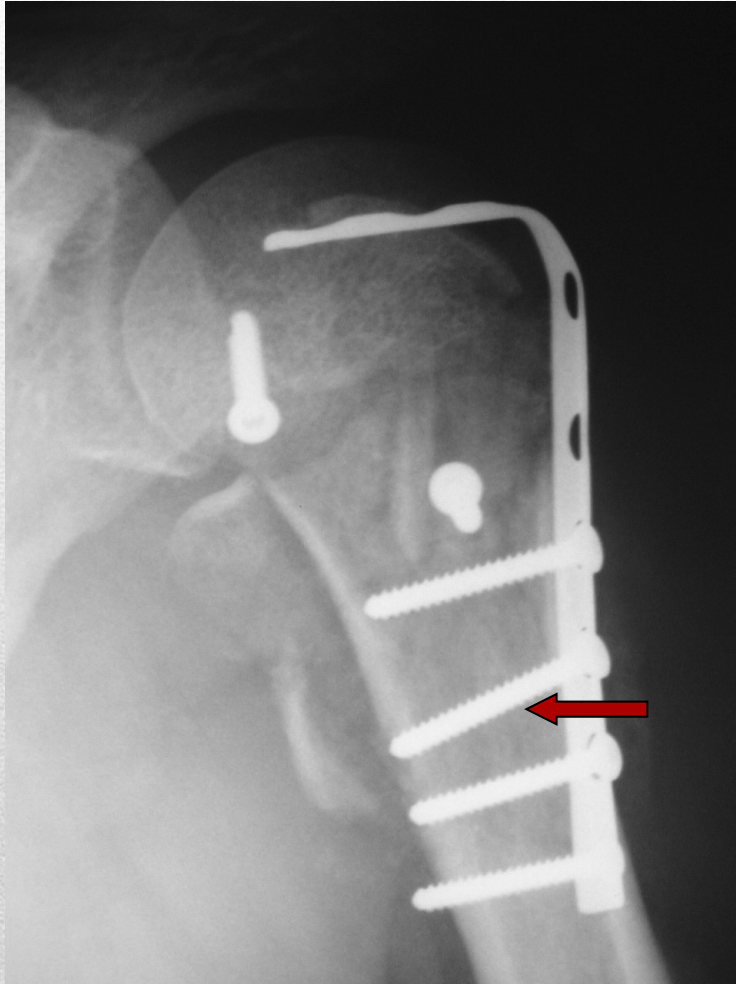


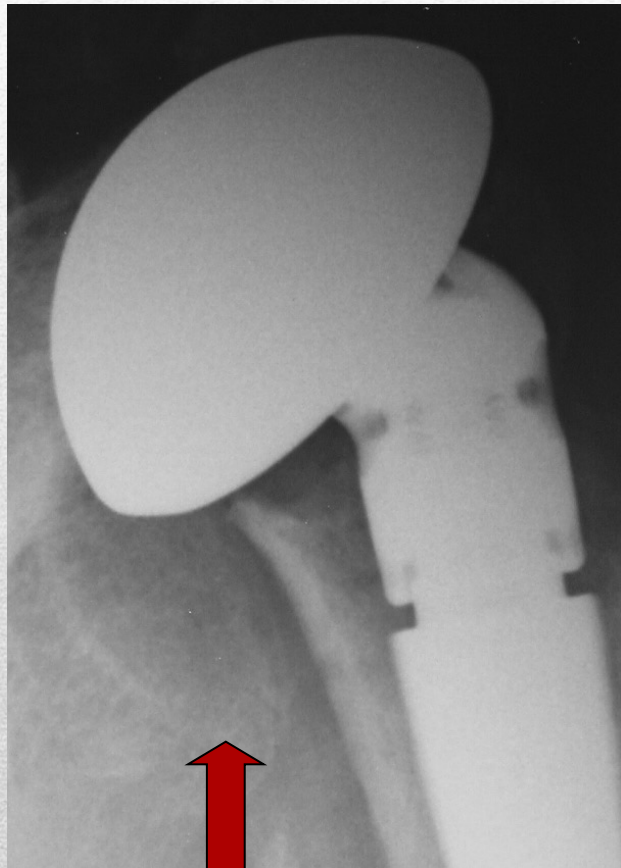
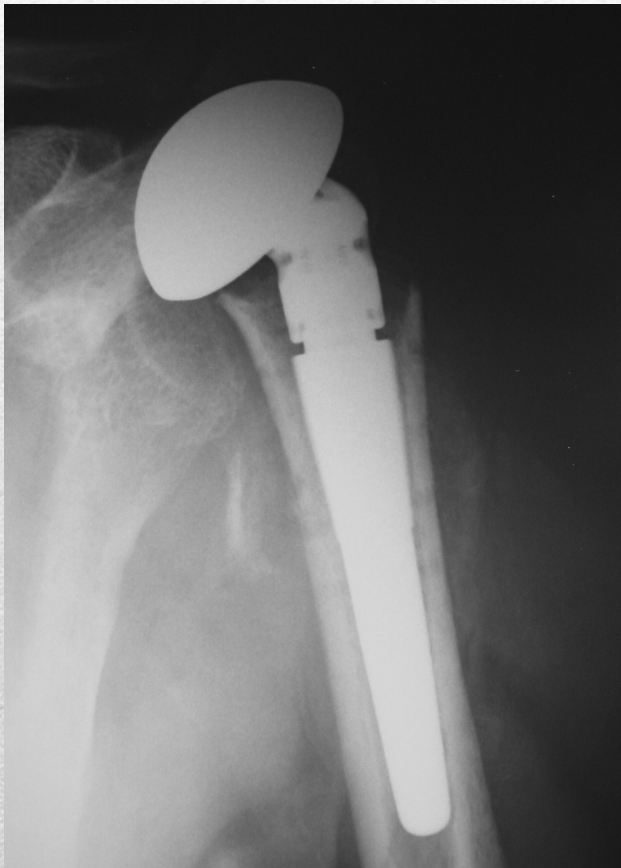


REVISIONE DA INFEZIONE SU MALPOSIZIONAMENTO

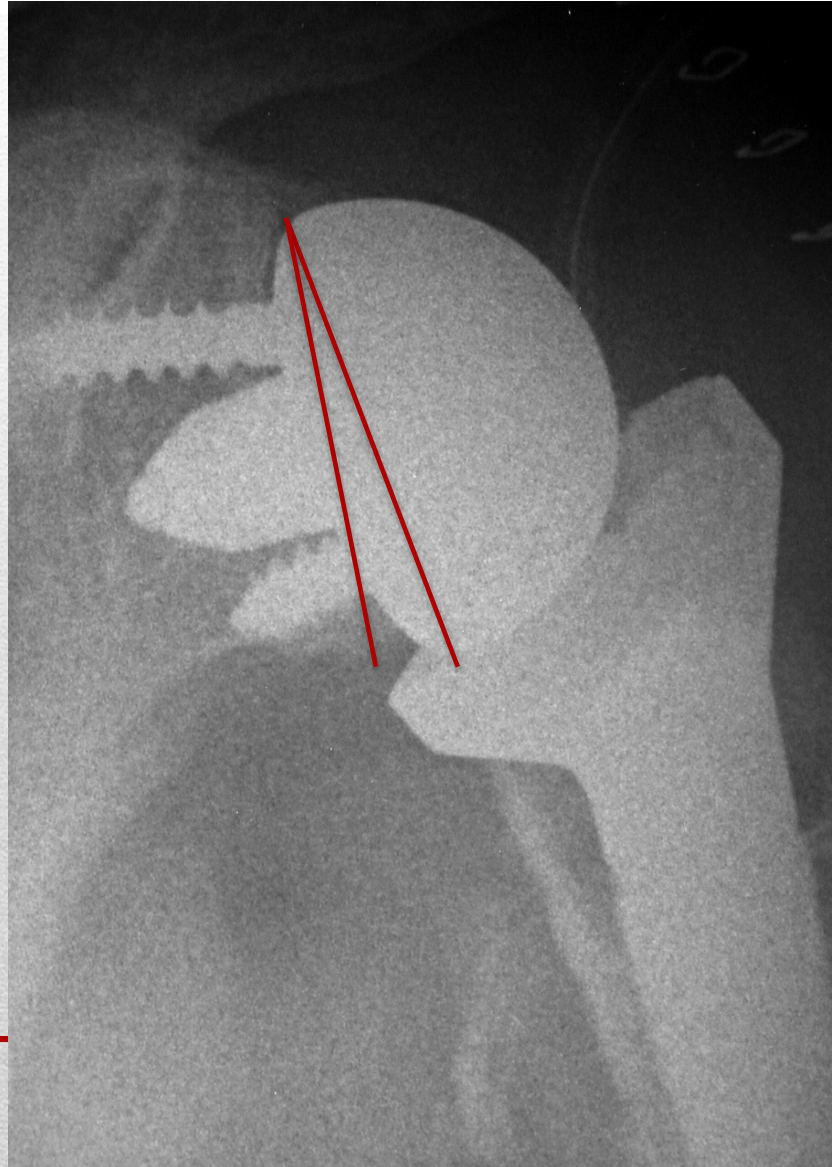

45 y.o. manual worker

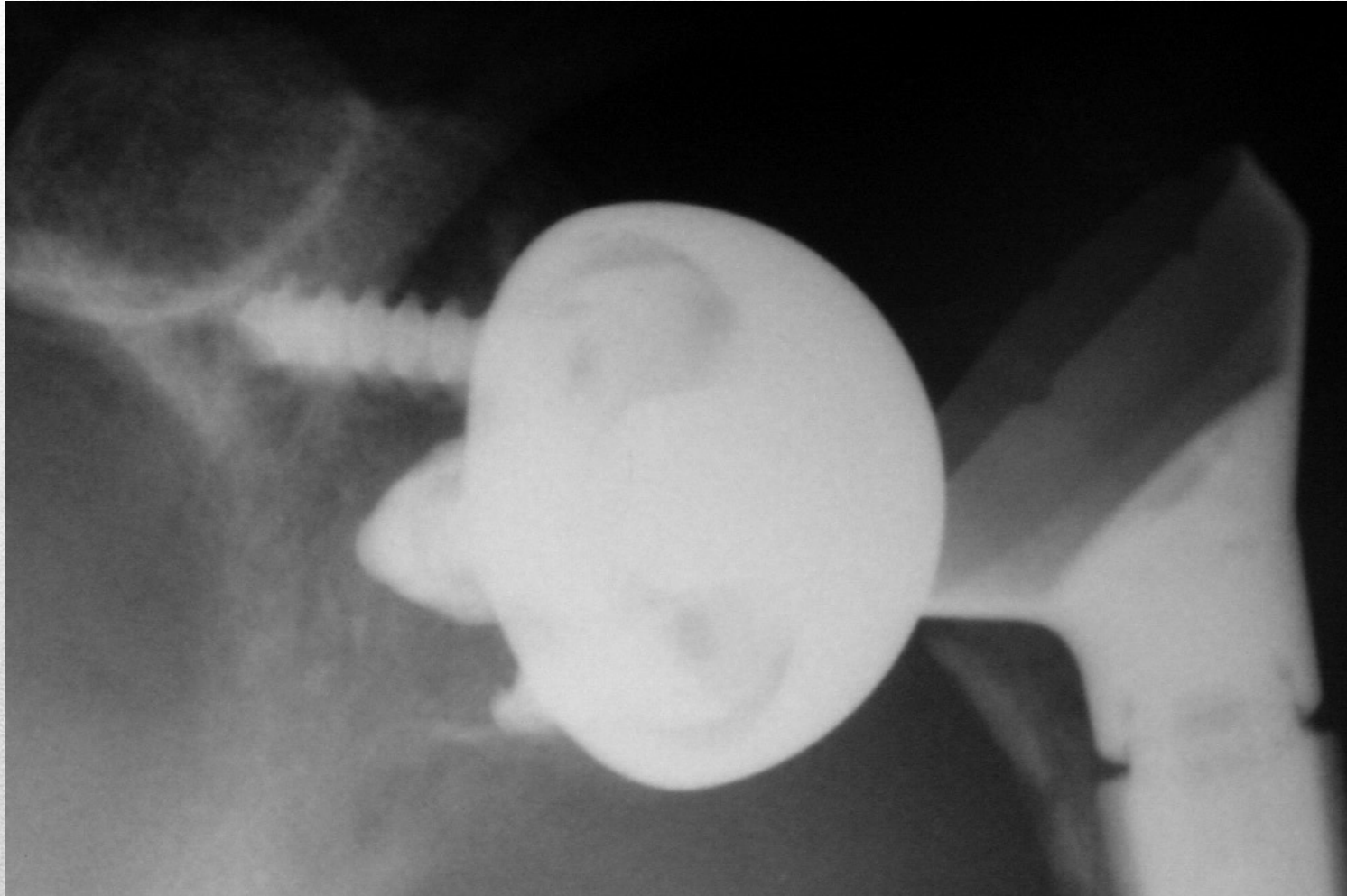




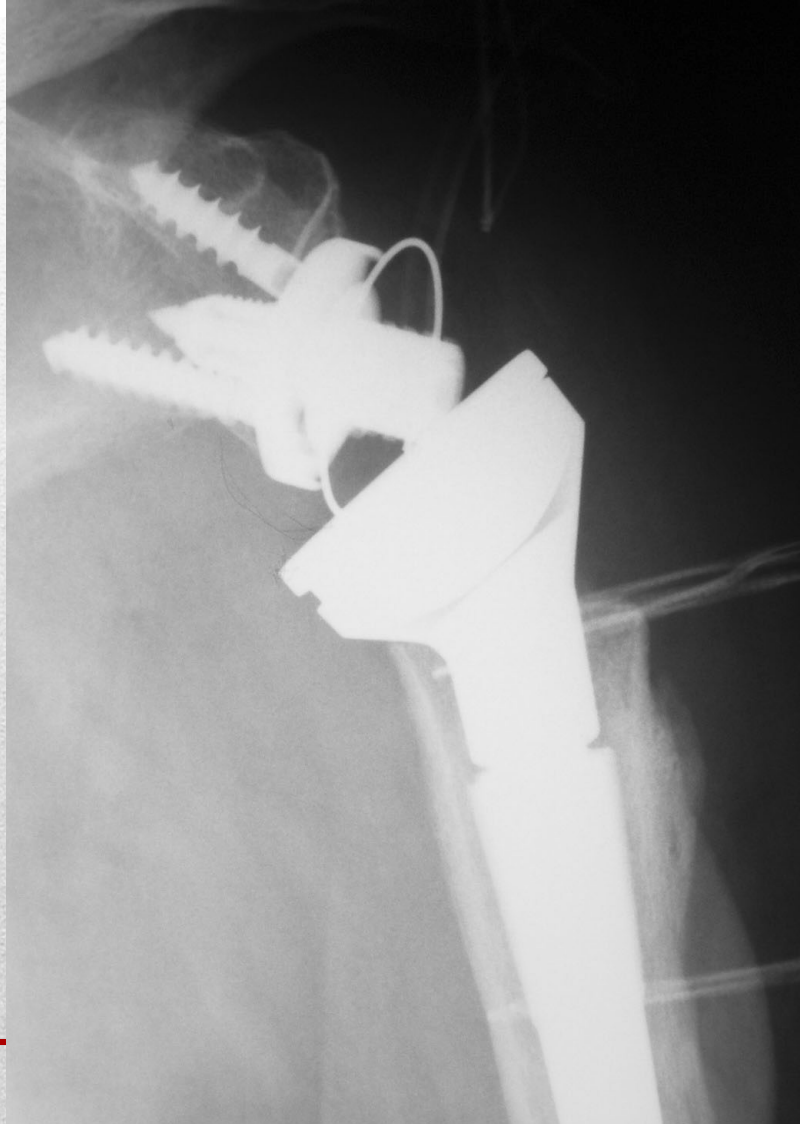
Reverse



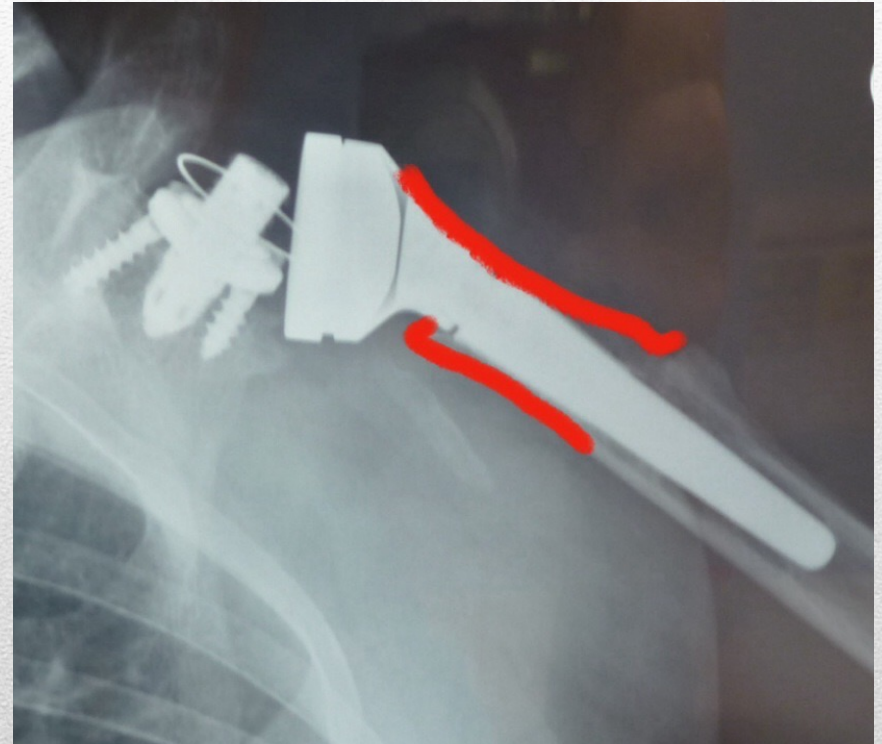
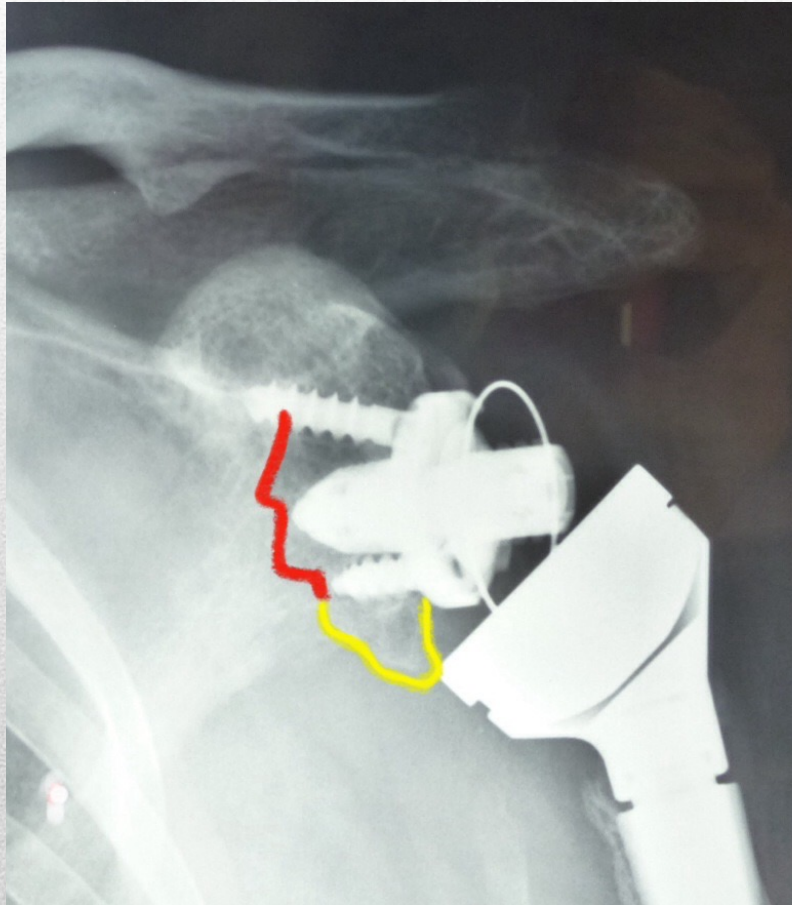
The reverse becomes unstable

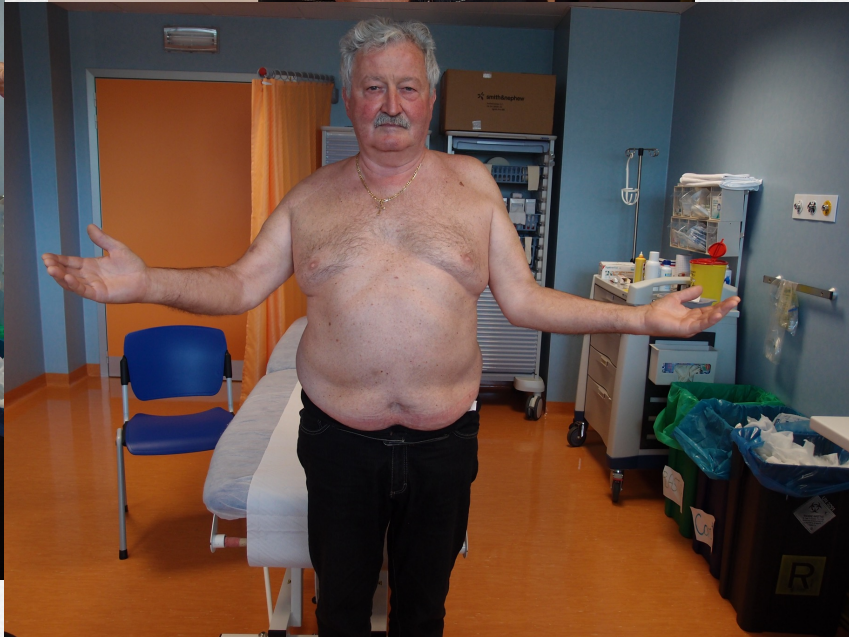
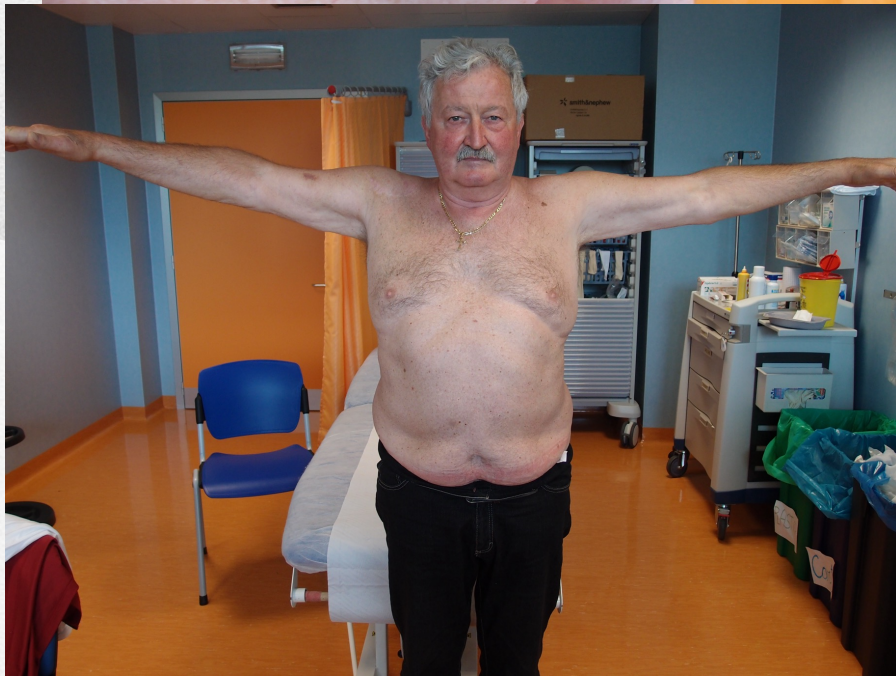
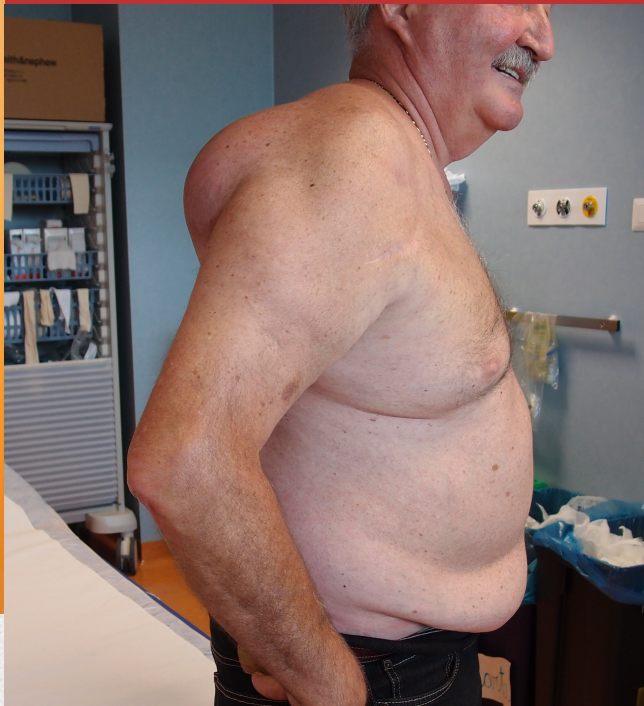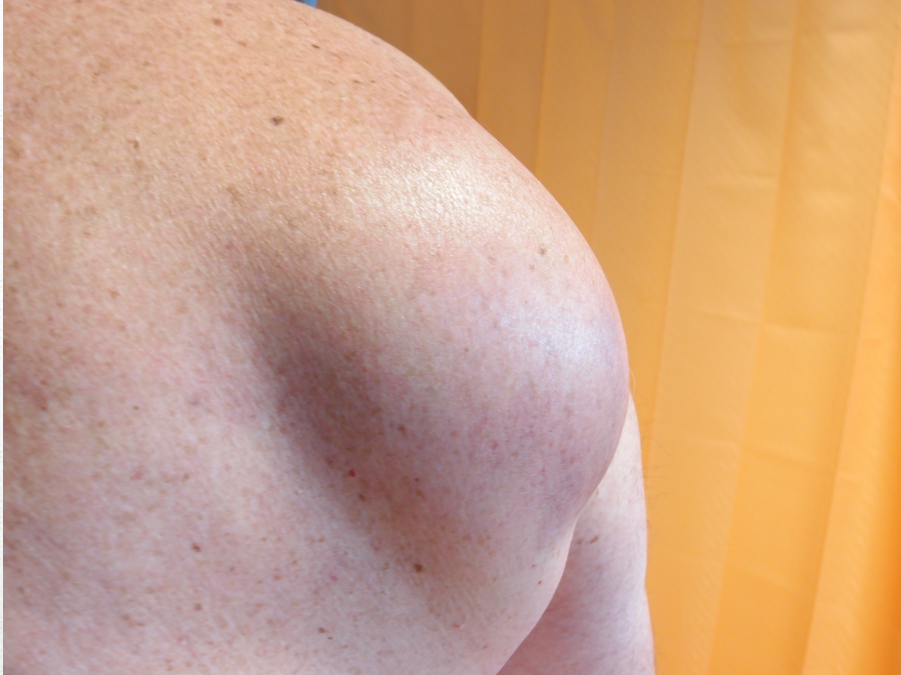Final: will it be the last?

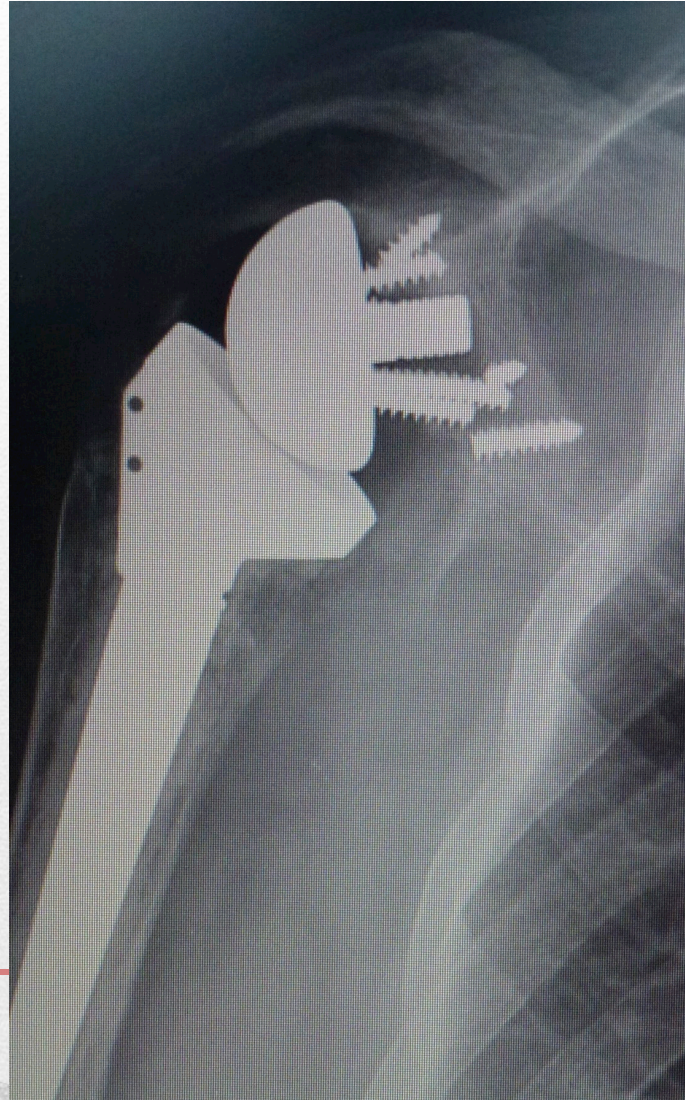


New trauma 8 years later (car accident)





Suddenly symptomatic



infections...

